Radiological and Biological Assessment of Immediately Restored Anterior Maxillary Implants Combined with GBR and Free Connective Tissue Graft

Roni Kolerman, DMD;* Joseph Nissan, DMD;† Arkadi Rahmanov, DMD;‡ Eran Zenziper, DMD;‡ Shimshon Slutzkey, DMD;§ Haim Tal, DMD, PhD#

ABSTRACT

Objectives: Radiologic and biologic assessment of immediately restored Implants combined with guided bone regeneration (GBR) and free connective tissue graft.

Methods: 1–4 year retrospective study involving 34 patients treated with maxillary immediately restored anterior single-implants. Soft tissue dimensions, radiographic bone loss, and biological and prosthetic complications were assessed.

Results: During the mean follow up period of 29 months the study group presented a mean mesial bone loss of 1.10 ± 0.39 mm (range: 0.5–2.4 mm), and mean distal bone loss of 1.19 ± 0.41 mm (range: 0.4–2.1 mm). Mean periimplant probing depth of 3.49 mm (SD $\pm$ 1.06) and 2.35 (SD $\pm$ 0.52) for the contralateral tooth (highly significant $p < 0.001$). Bleeding on probing was present in 29.4% of the examined implant supported crown sites and 10.4% of the contralateral teeth ($p < 0.001$).

Conclusions: Anterior maxillary single-tooth replacement, using GBR and connective tissue graft according to the concept of immediate implant placement, and non-functional restoration is an accepted treatment modality achieving favorable peri-implant soft tissue condition.

KEY WORDS: biologic complications, connective tissue, immediate loading, radiographic data, single-tooth implants

INTRODUCTION

Patients' increasing expectations for reduced treatment time comfort and esthetic had influenced clinical methods to improve treatment procedures for achieving the predictable outcome. The reduction of healing time by immediate multiple implant placement and loading has been previously described-presenting survival rates similar to these recorded using the conservative delayed techniques.[1–4]

Those promising results encouraged clinicians to use the knowledge for immediate loading of single implant cases.[5–7] However, there has been a concern that recession of the marginal periimplant mucosa may occur, which, in turn, may have an adverse effect on the final esthetic outcome.[8–10] Several factors were claimed to influence the frequency and extent of

*Lecturer, Department of Periodontology and Dental Implantology, the Maurice and Gabriela Goldschleger School of Dental Medicine, Tel-Aviv University, Tel-Aviv, Israel; †Professor, Department of Oral Rehabilitation, the Maurice and Gabriela Goldschleger School of Dental Medicine, Tel-Aviv University, Tel-Aviv, Israel; ‡Instructor, Department of Oral Rehabilitation, the Maurice and Gabriela Goldschleger School of Dental Medicine, Tel-Aviv University, Tel-Aviv, Israel; §Instructor, Department of Periodontology and Dental Implantology, the Maurice and Gabriela Goldschleger School of Dental Medicine, Tel-Aviv University, Tel-Aviv, Israel; #Professor and head, Department of Periodontology and Dental Implantology, the Maurice and Gabriela Goldschleger School of Dental Medicine, Tel-Aviv University, Tel-Aviv, Israel

Corresponding Author: Roni Kolerman, DMD, Lecturer, Department of Periodontology and Dental Implantology, the Maurice and Gabriela Goldschleger School of Dental Medicine, Tel-Aviv University, Tel-Aviv, Israel; e-mail: kolerman@netvision.net.il

DOI 10.1111/cid.12417

marginal mucosal recession, including peri-implant soft tissue biotype,[11] connection of a provisional crown immediately following implant insertion[12,13] condition and thickness of the facial bone,[14] orofacial position of the implant shoulder,[14–16] and grafting of the facial peri-implant marginal defects with autogenous bone or bone substitutes.[17,18] Implant positioning in relation to the bucco-oral and mesio-distal dimensions of the alveolar ridge are factors thought to influence the degree of bone remodeling[19] and may negatively influence the soft tissue topography and aesthetic outcome of therapy.[20] It has also been claimed that to maintain the stability of the buccal soft tissue, the buccal plate of bone should be at least 2 mm thick.[21] Since in most cases suffering from bone loss and/or ridge deformations there is lack of soft tissue in addition to lack of bone, it is advisable to improve the soft tissue cover as early as possible, preferably at the time of hard tissue augmentation. Thin tissue biotype is considered a major risk factor for advanced mid-buccal recession.[22] It has been proposed that increasing the thickness of the facial mucosa by the addition of a connective tissue (CT) graft beneath the facial flap at the time of implant placement may reduce this risk for recession.[23,24] The standard protocol with 2–3 consecutive surgeries in the same site may result in more tissue damage, scarring and loss. In addition, as the original gingiva may be preserved by the instant connection of a provisional restoration offering a mechanical support to the papilla and mid-facial gingival tissue, the need for additional soft tissue surgery may be eliminated.[12,13]

Consequently, the aim of the present retrospective study is to evaluate the radiologic and biologic outcomes of immediately restored implants combined with guided bone regeneration (GBR) and free connective tissue graft.

To our knowledge, although such combined procedure has been described before, these parameters have never been implicated to asses this combined soft and hard tissue procedure, and never been compared with contralateral natural teeth. These teeth can however be considered an ultimate reference in term of symmetry.

MATERIAL AND METHODS

Patient Selection Patient Population

Thirty-four patients of who had been treated consecutively by the senior author R.K (periodontist) during the years 2009–2013 with an immediate single implant in the aesthetic zone of the anterior maxilla (central and lateral incisors, and canines) were included in this case-control retrospective study. All implants were restored according to the concept of immediate nonfunctional loading. The study was approved by the human ethics committee of Tel-Aviv University, and patients signed an approved informed consent form. Patients were considered for the study on the basis of the following inclusion criteria:

1. Patients were at least 18 years old.
2. Extraction of a single tooth in the anterior esthetic zone of the upper jaw (Incisors, lateral incisors, canine) was indicated; both adjacent teeth mesial and distal to the extraction site were present.
3. The alveolar process presented at least 5 mm of bone apical to the alveolus of the failing tooth to ensure initial implant stability.
4. The insertion torque of the implant was 32Ncm or more[25]
5. After extraction and debridement the integrity of the buccal residual bone wall was compromised (thinner than 1mm, dehiscenced or fenestrated or combination of 2 of those defects) due to previous periodontal disease periapical pathology and or traumatic extraction.

Exclusion criteria were:

1. Smokers of more than 10 cigarettes a day, and smokers of less than 10 cigarettes a day who had not committed to a smoking cessation protocol.
2. Poor plaque control or lack of oral hygiene compliance.
3. Untreated or uncontrolled periodontal disease[26]
4. Systemic disease involving the oral mucosa in the esthetic zone.
5. Para-functional habits such as bruxism.
6. Uncontrolled diabetes.
7. Acute infection (with the present of pus, fistula) around the failing tooth,
8. Failure to achieve primary stability of at least 32 Ncm.
9. Intact bony sockets following extraction and debridement.

Surgical Protocol

A thorough pre-surgical evaluation included clinical images, periodontal chart, smoking habits,

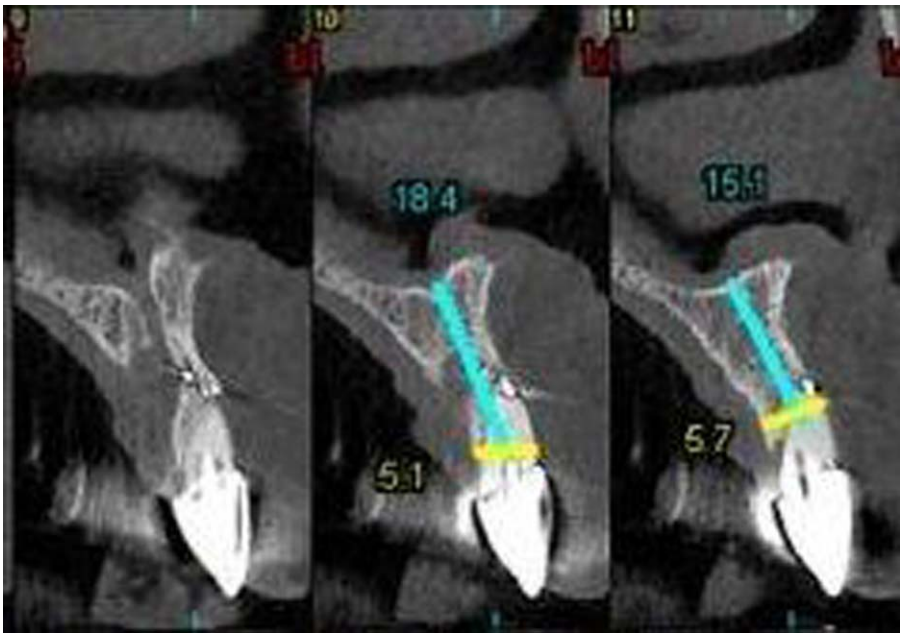

Figure 1 CT scan demonstrating missing coronal buccal bone and periapical radiolucency of hopeless left central incisor.

periodontal diagnosis, and full mouth periapical radiograph The morphology of the alveolar process at the implant site, the location of the incisive foramen and the root to be extracted as well as the presence of periapical pathologies were evaluated preoperatively using computed tomogram (CT) (Figure 1). All patients received comprehensive periodontal therapy, which included a cause-related course- consisting of 1-6 sessions of oral hygiene instructions, scaling and root planning whenever indicated and oral hygiene instructions until a Hygiene Index (HI)[27] of less than 10% was achieved, followed by surgical treatment whenever indicated. A one-minute rinse with chlorhexidine solution 0.2% (Tarodent mouthwash, Taro Pharmaceutical Industries Ltd, Haifa, Israel) was used by the patients prior to surgery.

Premedication with 875mg amoxicillin and clavulanic acid (Augmentin, Glaxo Smith Klein, Brentford, UK) was given one hour before surgery. Penicillin-sensitive patients were pre medicated with clindamycin HCL (Dalacin-C, Pfizer NV/SA, Belgium) 150 mg bid starting one hour before surgery. Antibiotic administration (Augmentin) was continued for one week (Dalacin 150 mg $\times$ 4 per day was utilized in penicillin-sensitive patients),and analgetic administration (Naproxen sodium 275 mg;, Narocin, Teva Pharm Ind Ltd., Petah-Tikva Israel) was given for pain reliever, and 0.2% chlorhexedine mouth rinse twice a day for 3 weeks.

All surgical procedures were performed and supervised by R.K. After the surgical site was anesthetized, mucoperiosteal flaps were elevated including intra crevicular incisions extending to the midfacial aspect of at least both adjacent teeth. This was followed by an atraumatic tooth extraction with an effort to maintain the integrity of the socket bone walls. Granulation tissue was removed using a spoon curette and a 3mm diamond bur (Strauss Company Raanana Israel). The drilling was conducted to the palatal wall. The osteotomy was designed to achieve as much implant engagement as possible with the bone apical and palatal borders of the extraction socket. Final drilling was performed using a drill measuring at least 1mm in diameter less than the implant diameter, depending on the residual bone density. Final sitting of the implant was achieved by an insertion torque of 32Ncm or more,[25] using a torque-controlled ratchet (MIS-Implants Technologies, Bar Lev Israel). Screw-type bone level titanium implants with a platform switch design (Seven, Lans MIS-Implants Technologies, Bar Lev Israel) were used. Proper implant positioning was considered of pivotal importance with the neighboring teeth essentially being served as reference for optimal implant positioning, (Figure 2). A minimum distance of 1 mm (measured with a periodontal probe) in M-D dimension between the implant shoulder and adjacent teeth was achieved in all the cases. In apico-coronal

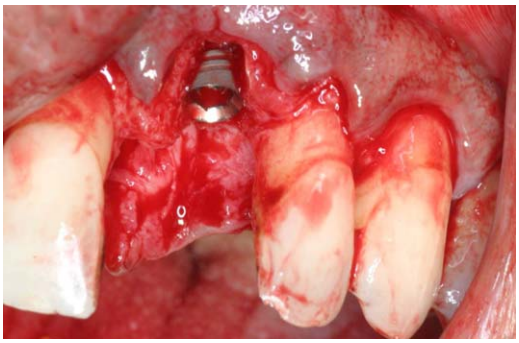

Figure 2 Dehiscence of buccal bone. The implant neck was flash with palatal bone.

direction the neck of the implant was flash with the palatal bone. In the orofacial dimension an effort was made to place the buccal neck of the implant at least 2 mm palatal to the buccal contour of neighboring teeth. After adaptation of an appropriate abutment of 0-25 degree, with1-3 mm height gingival neck and torqued with 15 Ncm, (Anthogyr, torque controlled ratchet-Botzer ergonomics, Israel) in all cases (not related to the socket configuration or defect morphology)after intra-marrow penetrations-allograft material 0.25-1 mm particle (FDBA-Raptos –Citagenics, Toronto Canada) was applied in the residual gap and in excess above the buccal wall. A resorbable collagen membrane (Bio-Gide, Geistlisch Pharma AG, Wolhusen, Switzerland) was applied in an apron manner above the bone graft (Figure 3). At this stage a free connective tissue graft was harvested from the palate and placed over the collagen membrane The buccal flap was corronally positioned after periosteal releasing incision and sutured to the palatal flap using Vicryl 4/0 sutures (Vicryl Rapid-Ethicon Johnson Belgium) (Figure 4).

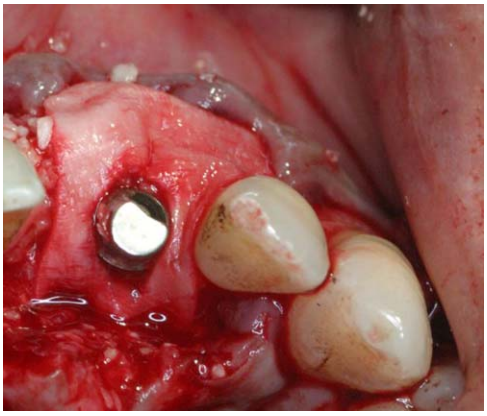

Figure 3 15 Degree abutment, Mineralized allograft (FDBA) + type 1 collagen membrane (Bio-Gide).

Figure 4 Corronally positioned flap and suturing.

Reconstructive Treatment Protocol

Abutment connection was followed by adaptation of a pre-fabricated non-functional acrylic temporary crown (no occlusal contacts in IC, and in protrusive and lateral movements) Six month after implant placement – after removal of the temporary crown and abutments, color coded transfers (MIS Implants Technologies, Bar Lev, Israel) were adapted-and radiographic verification of transfer adaptation was done. Impressions were taken using putty and silicone wash (Express, 3M. ESPE dental products St. Paul MN. USA) using the closed tray technique in metal stock trays. A master model with silicon image of the marginal gingival was prepared, and inter-arch relations were recorded. At the following appointment abutments were connected and the zirconia base was tried.

The permanent Zirconia crown was cemented after occlusal adjustment, and glazing with temporary cement (Temp- Bond Kerr corporation1717 West Collins Avenue CA US) (Figure 5).

Abutments were tightened to 35 Ncm using a prosthetic ratchet.

Figure 5 Final zirconia crown at 1 year.

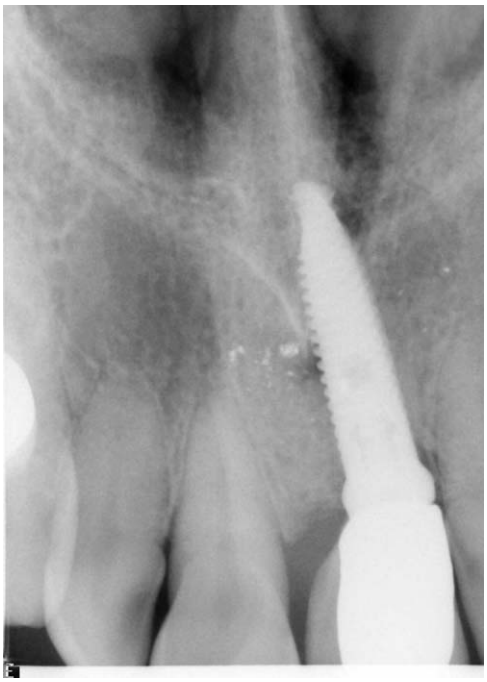

Figure 6 Final x-ray at data collection-3 years after crown adaptation.

Clinical Follow-Up Examination

Patients were clinically followed up at1, 2, 4 weeks and 3, 6, and 12 months postoperatively, and then annually. Patients have received personal oral hygiene programs and were seen and/or treated once every 3-6 months. Periodical maintenance visits were performed by dental hygienists and included plaque index and probing depth (PD) measurements and recording, de-plaquing, scaling and root planning as indicated.

Clinical Condition

- HI[27] percent of visible plaque measured on four sites per implant and tooth (mesial, midfacial, distal and palatal) at the soft tissue margin. The plaque was stained with a disclosing solution.
- Bleeding index-consisting a dichotomous recording of the absence or presence of bleeding after probing of the gingival sulcus per implant and tooth (mesial, midfacial, distal and palatal).
- PD was measured using a light probing force (approximately 25g) to the nearest mm using a periodontal probe (Hu– Friedy, Chicago, IL, USA).

Radiographic Evaluation

Postoperative periapical radiographs were performed immediately after implant placement, at the time of impression taking, at final crown installation, at the annual follow-up examinations and once again at the time of data collection during 2014 (Figure 6).

Standardized radiographs, with the film kept parallel (Schick technologies, Long Island, NY) using plastic film holders and the x-ray beam kept perpendicular.

Radiographic Data – The Distance from the Implant Shoulder to the Coronal Bone-to-Implant Contact (DIB)

The mesial and distal alveolar bone crest to implant shoulder distance was digitally measured using computerized dental radiography based on the parallel periapical x-rays (Schick technologies, Long Island, NY). Radiographic distortion was calculated by dividing the radiographic implant length by the actual one. Measurements were made at 12-48 month after the final crown adaptation, i.e., at the time of data collection. The value was calculated as the average of the obtained mesial and distal values. Bone loss of 1.5 mm during the first year and 0.2 for each successive year was considered "acceptable."[28] (The radiographic readings were performed by one experienced examiner not involved in the surgical or prosthetic treatment of the patient).

STATISTICAL ANALYSIS

Statistical analysis was performed with the SPSS 20.0 statistical analysis software (SPSS Inc., Chicago, IL, USA). Student's t test and analysis of variance (ANOVA) were used to assess the differences between groups according to demographic and clinical variables. Three-way ANOVA test was used to analyze the interaction effect between periodontal status, smoking and the cause of tooth extraction on radiographic bone loss. Due to the small sample size of the mild chronic gingivitis and periodontitis, periodontal diagnoses were grouped together into two groups' a. Gingivitis and mild chronic periodontitis and b. advanced chronic and aggressive periodontitis. The Pearson correlation coefficient test was used to test for correlation between age and outcome measures. P value <0.05 was accepted as significant. Biological parameters were analyzed using the Wilcoxon Signed Ranks (Exact) Test for PD and plaque index differences between implants and contralateral, and the Fisher's Exact test for differences in bleeding on probing (BOP).

TABLE 1 Included Patients and Implements Used

	No.	%
Gender		
Female	20	59
Male	14	41
Smokers		
<10 cigarettes per day	8	23.5
Non smokers	26	76.5
No. of implants	34	100
Implant length		
13 mm	5	15
16 mm	29	85
Implant platform		
3.3	10	30
3.75	17	50
4.2	6	17.5
5	1	2.5
Abutments		
Titanium	30	88
Zirconia	4	12
Implant site, Maxilla		
Central Incisor	12	35
Lateral Incisor	13	38
Canine	9	26.5

RESULTS

Thirty-four patients (14 males and 20 women) with age range 24 to 82years (mean 52.68 y' ± 14.35) who had been treated according to a strict protocol of extraction, simultaneous immediate implant placement, GBR and connective tissue graft procedure were the study sample (Table 1).

Twenty-seven (79.4%) of the patients suffered from chronic advanced adult periodontitis or aggressive periodontitis, whereas 7 (20.6%) were diagnosed with gingivitis and/or mild adult chronic periodontitis. Eighteen teeth (53%) were extracted due to periodontal disease, 9 (26.5%) due to root fracture, 4(11.7%) due to severe carious lesions, and 3(8.8%) due to external root resorption.

The relevant details of the study group including, gender, smoking status, implant length, width, abutment type and site of each implant are presented in Table 1. Implants diameter varied between 3.3 and 5mm with (mean 3.73 ± 0.37 mm) and implant length varied between 13-16 mm (mean 15.53 ± 1.08 mm) (Table 1).

Standard Soft Tissue Parameters

Patients performed good oral home care. At the 12 month observation period full mouth plaque index ranged between 5% to 40% with a mean of 18% (Table 2). Mean plaque score for implants and contralateral was 16.17% (SD ± 0.69) and 19.8% (SD ± 0.73) (Tables 2 and 3) (non-significant) mean PD at implant supported crown versus contralateral tooth was 3.21 mm (SD ± 0.91) and 2.56 (SD ± 0.56)at the mesial aspect, 3.59 mm (SD ± 1.13), 2.32 (SD ± 0.73) at the buccal, 3.38 mm (SD ± 1.35),2.56 (SD ± 0.61) at the distal and 3.76 mm (SD ± 1.23), and 1.97mm (SD ± 0.87) at the palatal aspect, resulting in a mean periimplant PD of 3.49 mm (SD ± 1.06) and 2.35 (SD ± 0.52) for the contralateral tooth(highly significant $p<0.001$) (Tables 2 and 3). BOP was present in 29.4% of the examined implant supported crown sites and 10.4% of the contralateral teeth ($p<0.001$) (Tables 2 and 3).

Radiographic Findings/DIB Values

At the time of data collection.1-4 years after implant placement, no implants were lost), 30 out of 34 (88%) implant were successful according to Alberktsson criteria (Table 4) showing no more than 1.5 mm of bone loss for the first year and additional 0.2 mm for each successive year.[28] During the follow up period of time the study group presented a mean mesial bone loss of 1.10 ± 0.39 mm (range: 0.5 mm −2.4 mm), and mean distal bone loss was 1.19 ± 0.41 mm (range: 0.4 mm −2.1 mm) (Table 4).

Biological Complications

Sub nasal or suborbital hematoma during the first week after surgery occurred in eight (23.5%) patients, and partial sloughing of the palatal donor site with secondary healing was noticed in seven patients (20.5%).

Technical Complications

During the follow-up period a total of 16 events of provisional crown loosening were observed in 10 patients. Three patients experienced 1 episode, five patients experienced 2 incidents and one patient experienced three incidents. Most provisional crowns could be re-cemented with temporary cement while two new crowns were made in two patients. Three abutment screws loosened before placement of the

TABLE 2 Biological Parameters of Implants versus Contralateral Teeth

Full mouth plaque index	HI	mean pd-c	Probing depth Contralateral				HI	mean pd-i	Probing depth Implant			
10	1.00	2.00	2	2	2	2	0	2.75	3	3	2	3
15	0.00	2.50	3	2	3	2	0	3.5	4	4	3	3
30	1.00	3.25	4	3	3	3	1	5	6	5	4	5
40	1.00	3.25	4	3	3	3	0	4.75	5	5	5	4
5	0.00	2.75	3	2	3	3	0	2.25	2	3	2	2
10	1.00	2.00	1	2	3	2	0	1.75	2	2	1	2
15	2.00	3.00	3	3	3	3	1	5.5	6	5	6	5
10	2.00	2.00	2	2	2	2	0	2.75	3	3	2	3
25	0.00	1.50	1	1	2	2	0	2.25	3	2	2	2
30	2.00	2.25	2	2	3	2	2	3.75	5	3	4	3
20	2.00	2.50	2	2	3	3	2	4	5	4	3	4
20	2.00	2.50	2	2	3	3	1	4.5	5	4	5	4
30	1.00	2.75	2	3	4	2	1	4.5	4	5	5	4
10	1.00	3.00	3	3	3	3	1	4.5	5	5	4	4
20	1.00	2.50	2	2	3	3	1	3.5	4	3	4	3
15	1.00	1.75	1	2	2	2	1	3.5	3	4	4	3
40	0.00	2.00	2	1	2	3	0	2.5	2	3	2	3
5	1.00	2.50	2	2	3	3	2	4	5	4	4	3
10	0.00	3.25	3	4	3	3	1	4.75	5	5	5	4
20	1.00	1.75	3	4	4	4	2	5.5	6	5	6	5
30	0.00	2.00	2	2	2	2	0	2.75	4	2	3	2
25	0.00	2.00	2	2	2	2	0	3.25	3	3	4	3
10	1.00	1.75	1	2	2	2	0	2.75	3	2	3	2
15	1.00	2.50	2	3	2	3	0	3.25	3	4	4	3
20	0.00	1.75	1	1	3	2	0	2.5	3	2	2	3
5	1.00	2.25	1	2	3	3	1	2.25	2	3	2	2
5	0.00	2.00	1	2	2	3	0	1.75	2	2	1	2
25	0.00	1.75	1	2	2	2	0	2	2	2	2	2
20	0.00	2.25	2	3	2	2	0	4	4	5	4	3
15	2.00	2.25	2	3	2	2	1	3.25	4	3	3	3
10	1.00	2.00	1	2	2	3	1	2.75	3	3	2	3
15	0.00	2.00	1	3	2	2	1	3.75	4	4	3	4
20	0.00	2.25	1	3	2	3	1	4.25	4	5	4	4
25	1.00	2.25	2	2	2	3	1	4.5	4	5	5	4
18.24	27.00	2.35	1.97	2.32	2.56	2.56	22.00	3.49	3.76	3.59	3.38	3.21
9.45	0.73	0.69	0.87	0.73	0.61	0.56	0.69	1.16	1.23	1.13	1.35	0.91
			14 bop						40 bop			sum BOP
			10.4						29.40%			SUM SD
												SUM SD

definitive crown. The provisional crown was removed and the abutment was tightened without any further complications. Two definitive crown lost retention in two patients. All crowns were re-cemented by temporary cement. No ceramic fracture occurred.

DISCUSSION

The cumulative survival rate for the immediate tooth replacement procedure in this study was 100% (34/34), whereas the success rate was 88% (30/34 implants) after a mean follow-up of 29 months. These figures are comparable to the mean marginal bone loss observed

TABLE 3 Clinical Conditions for Implant-Supported Crowns Compared with Contralateral Teeth [Mean (SD)]

Variable	Implant-supported crowns %	Contra lateral teeth %	Difference	
Plaque score (%)	16.17 (0.69)	19.8 (0.73)	−3.63	NS
Probing depth (mm)*	3.49 (1.06)	2.35 (0.52)	1.14	$p < 0.001$
Bleeding on probing†	29.4	10.4	19	$p < 0.001$

*Wilcoxon signed ranks (exact) test.
†Fisher's exact test.

TABLE 4 Radiographic Data

Sex	Age	Follow up months	Smoking	Distal bone loss	Mesial bone loss	Mean	Permitted bone loss
F	55	48	No	0.4	0.5	0.45	2.1
F	65	40	No	0.5	0.7	0.6	1.9
m	69	36	No	1	0.9	0.95	1.9
m	47	36	Light	1.5	1.6	1.55	1.9
m	26	12	Light	1	0.8	0.9	1.5
m	33	12	No	0.4	0.8	0.6	1.5
f	55	12	No	2.1	2.4	2.25*	1.5
f	35	40	No	1	1	1	1.9
m	24	12	Light	0.9	1	0.95	1.5
f	52	45	Light	1.3	0.7	1	1.9
f	56	45	Light	1.3	1.3	1.3	1.9
f	57	12	No	1.6	1.4	1.5	1.5
m	59	12	No	1.7	1.4	1.55*	1.5
m	56	28	Light	1.2	1.4	1.3	1.7
f	68	36	No	1.2	1.1	1.15	1.9
f	68	40	Light	1.2	1.1	1.15	1.9
m	54	40	No	0.6	0.8	0.7	1.9
f	52	44	No	1.3	1.1	1.2	1.9
f	54	36	No	1.6	1.4	1.5	1.9
f	50	12	No	1.6	2	1.8*	1.5
m	58	36	Light	1	1.2	1.1	1.9
f	40	40	No	1.6	1	1.3	1.9
m	65	24	No	1.3	0.9	1.1	1.7
f	74	40	No	1.5	1.4	1.45	1.9
m	62	24	No	0.8	0.6	0.7	1.7
f	37	12	No	0.9	1.2	1.1	1.5
f	52	36	No	0.7	0.6	0.65	1.9
m	27	48	No	0.7	1	0.85	2.1
m	32	12	No	1.7	1.4	1.55*	1.5
f	40	24	No	1.3	0.9	1.1	1.7
f	59	12	No	1.1	1.1	1.1	1.5
f	66	24	No	1.2	0.8	1	1.7
M	62	24	No	1.3	0.9	1.1	1.7
F	82	36	No	1.8	1.1	1.45	1.9
Mean	52.68	29.12		1.19	1.1	1.15	
SD	14.35	12.96		0.41	0.39	0.38	

Light smoking <10 cigarettes per day.
*Survival.

for delayed loaded implants as well as for immediately loaded implants after the first year.[28–33]

Although the buccal bone plate was compromised in our study group, our success rates are comparable to the data reported when single implants replaced failing teeth in the esthetic zone with an intact labial bony plate.[29,34]

The relatively low (1.15 ± 0.38) mean marginal bone loss per implant measured 12-48 months after implant placement may be attributed to the placement of bone grafts and membranes which enhanced the bone fill and concomitantly enlarged the buccal bone plate,[21,35] as well as to the compliance of the patients.

The low mean PD of implants (3.49 ± 1.06) at the 12-month examination indicated healthy peri-implant soft tissue, and is in line with previous studies.[15,23] In spite of the fact that there were no significant differences in the presence of plaque between implant restorations and teeth, probing induced significantly more bleeding around implants. This is, however, a common finding[36,37] as a result of an "inflammatory cell infiltrate" possibly induced by microleakage at the implant–abutment interface[38] and the subgingival position of the restoration border.[31]

PD was also considerably higher around implants when compared with contralateral teeth, which can be considered a normal phenomenon, especially around two-piece implants.[39–41]

In this study, all the socket walls were compromised in their vertical and/or horizontal dimensions mainly due to previous periodontal disease involving the tooth to be extracted and replaced. No fewer than 53% of the teeth were extracted due to advanced periodontal disease. The other teeth were extracted due to caries, external resorption or deep horizontal fractures of crown, and 79.4% of the patients were diagnosed with advanced or aggressive periodontitis.

The surgical technique applied in this study is characterized by the use of non–cross-linked collagen membranes in combination with mineralized allograft granules (FDBA). The FDBA granules offer good volume stability for the buccal bone augmentation because of their low substitution rate.[35]

The collagen membranes were used to diminish the risk for membrane infection if a soft tissue dehiscence were to occur postoperatively[42,43]

Reports in the literature on assessments of biological complications of immediately placed and provisionally restored single-tooth implants are sparse.[44,45]

The biological complications that occurred resolved within two weeks (hematoma) and one month (sloughing of the palatal donor site) after antibiotic administration for one additional week and topical application of chlorhexidine 0.2% gel. The most frequently occurring technical complication was loosening of abutment screws and de-cementation of the provisional crown.

In this study, hard- and soft-tissue augmentation concomitantly with immediate implant placement was employed to achieve stability of the implant within the hard and soft tissue.

Our results suggest that in spite of the bone deficiencies in the buccal walls of the sockets, the present approach results in success rates similar to other methods of immediate loading or restoration, both clinically and radio graphically.

REFERENCES

1. Bergkvist G, Sahlholm S, Karlsson U, Nilner K, Lindh C. Immediately loaded implants supporting fixed prostheses in the edentulous maxilla: a preliminary clinical and radiologic report. Int J of Oral Maxillofac Implants 2005; 20:399–405.
2. Degidi M, Piatteli A, Felice P, Carinci F. Immediate functional loading of edentulous maxilla: a 5-year retrospective study of 388 titanium implant. J Periodontol 2005; 76:1016–1024.
3. Ibanez JC, Tahhan MJ, Zamar J, et al. Immediate occlusal loading of double acid-etched surface titanium implants in 41 consecutive full-arch cases in the mandible and maxilla: 6 to 74- month results. J Periodontol 2005; 76: 1972–1981.
4. Ostman PO, Hellman M, Sennerby L. Direct implant loading in the edentulous maxilla using a bone density-adapted surgical protocol and primary implant stability criteria for inclusion. Clinical Oral Implants Res 2005; 7: 560–569.
5. Andersen E, Haanaes HR, Knusten BM. Immediate loading of single-tooth ITI implants in the anterior maxilla: a prospective 5-year pilot study. Clin Oral Implant Res 2002; 13:281–287.
6. Chausu G, Chausu S, Tzohar A, Dayan D. Immediate loading of single tooth implants: immediate versus non-immediate implantation. A clinical report. Int J of Oral Maxillofac Implant 2001; 16:267–272.
7. Cooper L, Felton DA, Kugelberg CF, et al. A multicenter 12-month evaluation of single-tooth implants restored 3 weeks after 1-stage surgery. Int J of Oral Maxillofac Implant 2001; 16:182–192.

8. Grunder U. Stability of the mucosal topography around single-tooth implants and adjacent teeth: 1-year results. Int J Periodontics Restorative Dent 2000; 20:11–17.
9. Lindeboom JA, Tjiook Y, Kroon FH. Immediate placement of implants in periapical infected sites: a prospective randomized study in 50 patients. Oral Surg Oral Med Oral Pathol Oral Radiol 2006; 101:705–710.
10. Norton MR. A short-term clinical evaluation of immediately restored maxillary TiOblast single-tooth implants. Int J of Oral Maxillofac Implant 2004; 19:274–281.
11. Kois JC. Predictable single tooth peri-implant esthetic: five diagnostic keys. Compend Contin Edu Dent 2004; 25:895–900.
12. Wöhrle PS. Single-tooth replacement in the aesthetic zone with immediate provisionalization: fourteen consecutive case reports. Pract Period Aesthetic Dent 1998; 10: 1107–1114.
13. Jemt T. Restoring the gingival contour by means of provisional resin crowns after single-implant treatment. Int J Period Restorative Dent 1999; 19:20–29.
14. Grunder U, Gracis S, Capelli M. Influence of the 3-D bone-to-implant relationship on esthetics. Int J Period Restorative Dent 2005: 25:113–119.
15. Buser D, Martin W, Belser UC. Optimizing esthetics for implant restorations in the anterior maxilla: anatomic and surgical considerations. Int J of Oral Maxillofac Implant 2004; 19:43–61.
16. Evans CD, Chen ST. Esthetic outcomes of immediate implant placements. Clin Oral Implant Res 2008; 19:73–80.
17. Zitzmann NU, Scharer P, Marinello CP. Long-term results of implants treated with guided bone regeneration: a 5-year prospective study. Int J of Oral Maxillofac Implant 2001; 16:355–366.
18. Chen ST, Darby IB, Adams GG, Reynolds EC. A prospective clinical study of bone augmentation techniques at immediate implants. Clin Oral Implant Res 2005; 16: 176–184.
19. Esposito M, Ekestubbe A, Grondahl K. Radiological evaluation of marginal bone loss at tooth surfaces facing single Branemark implants. Clin Oral Implant Res 1993; 4: 151–157.
20. Cardaropoli G, Lekholm U, Wennstrom JL. Tissue alterations at implant-supported single-tooth replacement: a 1-year prospective clinical study. Clin Oral Implant Res 2006; 17:165–171.
21. Spray JR., Black CG, Morris HF, Ochi S. The influence of bone thickness on facial marginal bone response: stage 1 placement through stage 2 uncovering. Ann Periodontol 2000; 5:119–128.
22. Kan JY, Rungcharassaeng K, Lozada J, Zimmerman G. Facial gingival tissue stability following immediate placement and provisionalization of maxillary anterior single implants: a 2- to 8-year follow-up. Int J of Oral Maxillofac Implant 2011; 26:179–187.
23. Kan JY, Rungcharassaeng K, Lozada J. Bilaminar subepithelial connective tissue grafts for immediate implant placement and provisionalization in the esthetic zone. J California Dental Assoc 2005; 33:865–871.
24. Grunder U. Crestal ridge width changes when placing implants at the time of tooth extraction with and without soft tissue augmentation after a healing period of 6 months: report of 24 consecutive cases. Int J Period Restorative Dent 2011; 31:9–17.
25. Chung S, McCullagh A, Irinakis T. Immediate loading in t the maxillary arch: evidence-based guidelines to improve success rates: a review. J Oral Implantol 2011; 37:610–621.
26. Chen ST, Buser D. Esthetic outcomes following immediate and early implant placement in the anterior maxilla-a systematic review. Int J of Oral Maxillofac Implant 2014; 29:186–215.
27. O'Leary TJ, Drake RB, Naylor JE. The plaque control record. J Periodontol 1972; 43:38.
28. Alberktsson T, Zarb G, Wotthington P, Eriksson RA. The long – term efficacy of currently used dental implants: a review and proposed criteria of success. Int J Oral Maxillofac Implant 1986; 1:11–25.
29. Kan JYK, Runcharassaeng K, Lozada J. Immediate placement and provisionalization of maxillary anterior single implants: 1-year prospective study. Int J of Oral Maxillofac Implant 2003; 18:31–39.
30. De Kok IJ, Chang SS, Moriarty JD, Cooper LF. A retrospective analysis of peri-implant tissue responses at immediate load/provisionalized microthreaded implants. Int J of Oral Maxillofac Implant 2006; 21:405–412.
31. Jemt T, Pettersson P. A 3-year follow-up study on single implant treatment. J Dent 1993; 21:203–208.
32. Laney WR, Jemt T, Harris D, et al. Osseointegrated implants for single tooth replacement: progress report from a multi-center prospective study after 3 years. Int J of Oral Maxillofac Implant 1994; 9(1):49–54
33. Goodacre CJ. Kan JYK, Rungcharassaeng K. Clinical complications of osseointegrated implants. J Prosthetic Dent 1999; 81:537–552.
34. Barone A, Rispoli L, Vozza I, Quaranta A, Covani U. Immediate restoration of single implants placed after tooth extraction. J Periodontol 2006; 77:1914–1920.
35. Kolerman R, Nissan J, Tal H. Combined Osteotome induced ridge expansion and guided bone regeneration with simultaneous implant placement: a biometric study. Clin Implant Dent Relat Res 2013; 25:1–14.
36. Chang M, Wennström JL, Ödman P, Andersson B. Implant supported single-tooth replacements compared to contralateral natural teeth. Crown and soft tissue dimensions. Clin Oral Implant Res 1999; 10:185–194.

37. Lorenzoni M, Pertl C, Polansky R, Wegscheider W. Guided bone regeneration with barrier membranes – a clinical and radiographic follow-up study after 24 months. Clin Oral Implant Res 1999; 10:16–23.
38. Piattelli A, Vrespa G, Petrone G, Iezzi G, Annibali S, Scarano A. Role of the microgap between implant and abutment: a retro-spective histologic evaluation in monkeys. J Periodontol 2003; 74:346–352.
39. Lekholm U, Adell R, Lindhe J, et al. Marginal tissue reactions at osseointegrated titanium fixtures. A cross-sectional retrospective study. Int J of Oral Maxillofac Implant 1986; 15:53–56.
40. Proussaefs P, Kan J, Lozada J, Kleinman A, Farnos A. Effects of immediate loading with threaded hydroxyapatite-coated root-form implants on single premolar replacements: a pre-liminary report. Int J Oral Maxillofac Implant 2002; 17:567–572.
41. Cosyn J, De Rouck T. Aesthetic outcome of single-tooth implant restorations following early implant placement and guided bone regeneration: crown and soft tissue dimensions compared with contralateral teeth. Clin Oral Implant Res 2009; 20:1063–1069.
42. Stavropoulos F, Dahlin C, Ruskin JD, Johansson CA. Comparative study of barrier membranes as graft protectors in the treatment of localized bone defects. An experimental study in a canine model. Clin Oral Implant Res 2004; 15:435–442.
43. Buser D, Dula K, Lang NP, Nyman S. Long-term stability of osseointegrated implants in bone regenerated with the membrane technique. 5-year results of a prospective study with 12 implants. Clin Oral Implant Res 1996; 7:175–183.
44. De Rouck T, Collys K, Cosyn J. Single-tooth replacement in the anterior maxilla by means of immediate implantation and provisionalization: a review. Int J of Oral Maxillofac Implant 2008; 23:897–904.
45. Kohberg P, Ahlmann S, Gotfredsen E, Andersen NT, Isidor F, Schou S. Immediate placement and provisionalization of single-tooth implants involving a definitive individual abutment: a clinical and radiographic retrospective study. Clin Oral Implant Res 2013; 24:652–658.