Clinical Radiographic and Histomorphometrical Analysis of Maxillary Sinus Augmentation using Synthetic Bone Substitute – 4Bone™ SBS

R. Kolerman*, E. Barnea**, H. Tal *

***Department of Periodontology; ** Department of Oral Rehabilitation**

The Maurice and Gabriela Goldschleger School of Dental Medicine. Tel Aviv University, Tel Aviv, Israel.

Aims: To evaluate clinically, histologically and histomorphometrically the efficiency of a synthetic bone substitute (**4Bone™ SBS -** 60% HA & 40% β-TCP) using **internal-external sub - Schneiderian collagen membrane for sinus augmentation procedures.**

Materials and methods: The lateral antrostomy technique was performed using 4Bone. A double (internal-external) collagen membrane was used in 12 non-smoking patients. Core biopsies were harvested 9 months after sinus floor augmentation. Biopsies were stained with H&E. Histomorphometrical measurements were made using the point-counting procedure. The percentage fraction of each of the following was calculated for each section: newly formed bone (NB), residual graft material (G), bone marrow and connective tissue (CT). The osteoconductive value was calculated by measuring the contact area between the graft particles and the newly formed bone divided by the total circumferences of the graft particles, using a microscope equipped with a drawing tube.
.

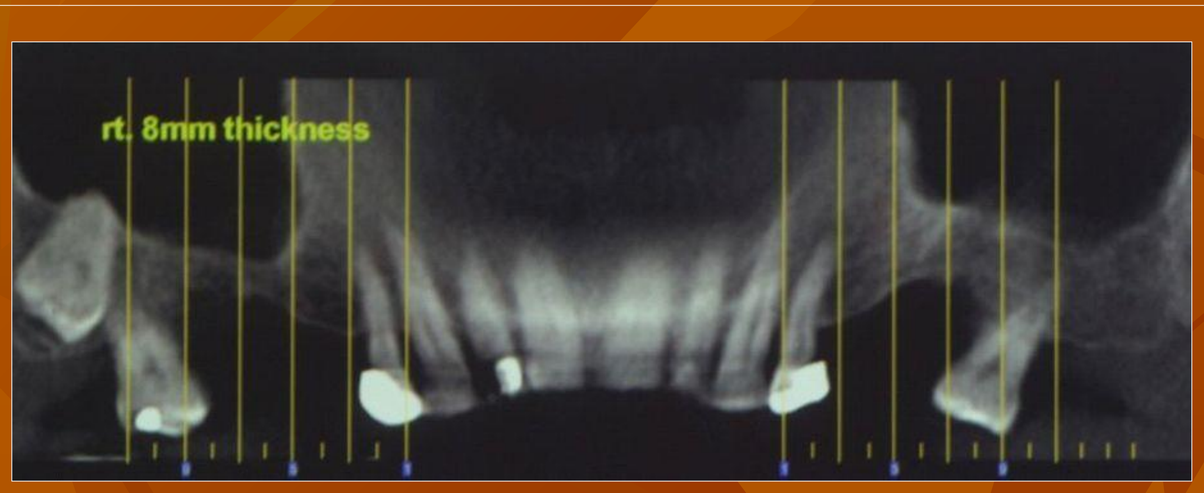

Fig. 1: MD- Initial radiographic presentation showing the enlarged sinus cavity.

Fig. 2: MD- 9 months after sinus grafting showing stability of the grafted material.

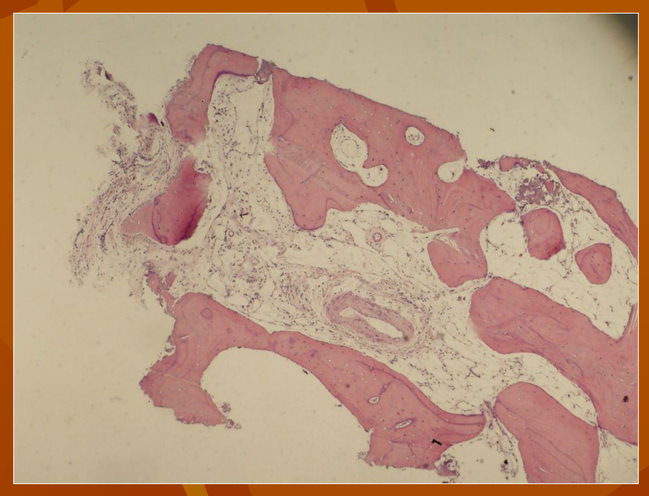

Fig. 3: MD- 9 months biopsy. Pristine bone. (Hematoxilyn & Eosin, x100 magnification)

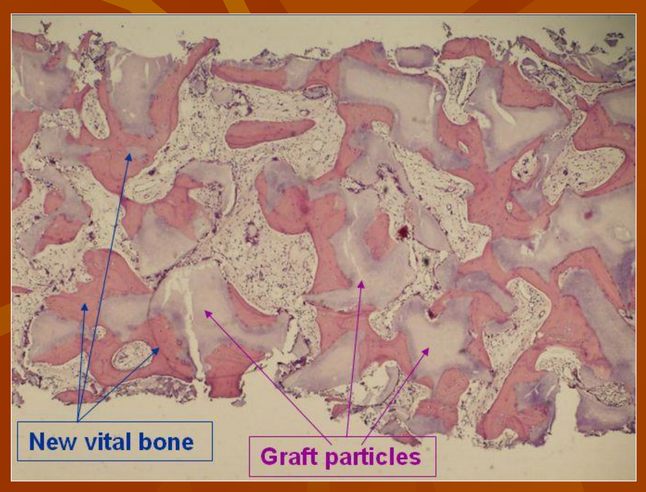

Fig. 4: MD- 9 months biopsy after grafting with 4Bone SBS. Graft particles surrounded by vital bone and connective tissue. (Hematoxilyn & Eosin, x100 magnification)

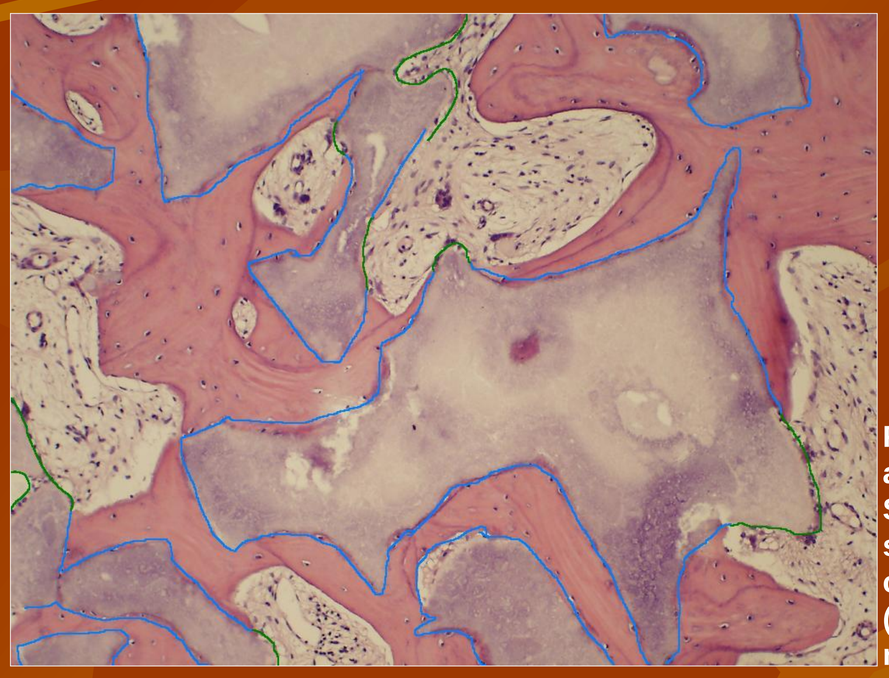

Fig. 5: MD- 9 months biopsy after grafting with 4Bone SBS. Graft particles surrounded by vital bone and connective tissue. (Hematoxilyn & Eosin, x400 magnification)

Results: Graft particles were observed in all specimens surrounded by newly formed bone in direct connection or by soft tissue marrow. The histometrical analysis of the sections showed: Average NB - 28%, Average G - 41% Average CT - 31%. Mean osteoconductive value - 57.8%.

Conclusion: 4Bone SBS is biocompatible and osteoconductive permitting new bone formation similar to deproteinized bovine bone mineral, and allograft materials when used in conjunction with an internal sub- Schneiderian collagen membrane for sinus augmentation procedures.