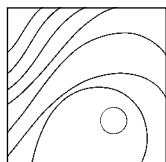


## Histomorphometric Analysis of Newly Formed Bone After Bilateral Maxillary Sinus Augmentation Using Two Different Osteoconductive Materials and Internal Collagen Membrane



Roni Kolerman, DMD\*/Gili R. Samorodnitzky-Naveh, DMD\*\*  
Eitan Barnea, DMD\*\*/Haim Tal, DMD, MDent, PhD\*\*\*

*Deproteinized bovine bone mineral (DBBM) and human freeze-dried bone allograft (FDBA) were compared in five patients undergoing bilateral maxillary sinus floor augmentation using DBBM on one side and FDBA on the contralateral side. After 9 months, core biopsy specimens were harvested. Mean newly formed bone values were 31.8% and 27.2% at FDBA and DBBM sites, respectively ( $P = .451$ ); mean residual graft particle values were 21.5% and 24.2%, respectively ( $P = .619$ ); and mean connective tissue values were 46.7% and 48.6%, respectively ( $P = .566$ ). Within the limits of the present study, it is suggested that both graft materials are equally suitable for sinus augmentation. (Int J Periodontics Restorative Dent 2012;32:e21–e28.)*

\*Instructor, Department of Periodontology, The Maurice and Gabriela Goldschleger School of Dental Medicine, Tel-Aviv University, Tel-Aviv, Israel.

\*\*Instructor, Department of Oral Rehabilitation, The Maurice and Gabriela Goldschleger School of Dental Medicine, Tel-Aviv University, Tel-Aviv, Israel.

\*\*\*Professor and Head, Department of Periodontology, The Maurice and Gabriela Goldschleger School of Dental Medicine, Tel-Aviv University, Tel-Aviv, Israel.

Correspondence to: Dr Roni Kolerman, Department of Periodontology, The Maurice and Gabriela Goldschleger, School of Dental Medicine, Tel Aviv University, Tel Aviv, Israel; email: daniaron@netvision.net.il.

Alveolar bone resorption in the posterior maxilla is a common pathologic process following tooth loss and periodontal disease.<sup>1</sup> Lack of sufficient alveolar bone height in this area often makes the placement of standard implants impossible. Presently, the most common intervention used to increase bone height in this region is grafting of the maxillary sinus with autogenous bone or with bone replacement grafts,<sup>2</sup> a procedure referred to as *sinus floor elevation*. Tatum<sup>3</sup> first described this procedure in 1977. Boyne and James<sup>4</sup> coined the term "sinus lift procedure" in 1980 and described the surgical intervention of raising the maxillary sinus floor by elevating the sinus mucosa and interposing bone grafts between the mucosa and bony sinus floor. Eventually, adequate bone formation was obtained to anchor dental implants of optimal length.<sup>4</sup> The technique has been modified several times over the years.<sup>5,6</sup>

Since the early 1980s, various grafting materials have been used successfully to augment the maxillary sinus. Many consider autogenous

bone as the gold standard,<sup>4</sup> followed by a bone replacement graft, such as resorbable or nonresorbable hydroxyapatite preparations,<sup>5,7,8</sup> xenografts,<sup>8,9</sup> bioglass, and calcium sulfate.<sup>1</sup> Growth factors<sup>10</sup> alone or in combination with carrier materials are recent additions.<sup>11</sup>

A popular bone replacement graft is deproteinized bovine bone mineral (DBBM), which has been extensively investigated in animal<sup>12</sup> and human<sup>8,9</sup> trials. This material is osteoconductive and biocompatible in osseous regenerative procedures. Many believe that mineralized materials are more successful in sinus augmentation procedures than demineralized ones.<sup>13</sup> Additionally, demineralized and nondemineralized freeze-dried bone allografts (DFDBA, FDBA) have been investigated.<sup>13-15</sup> It has been stated that DFDBA is less effective in sinus augmentation procedures,<sup>13,16</sup> while FDBA results in more new bone growth.<sup>14</sup>

To the best of the authors' knowledge, very few histologic or histomorphometric studies that compare FDBA and DBBM in human sinus augmentation have been published.<sup>15,17</sup> The purpose of this study was to compare the use of FDBA and DBBM clinically, histologically, and histomorphometrically in sinus augmentation procedures.

## Method and materials

Five adult women between 54 and 65 years of age (mean, 58.8 years) with no systemic disorders were

selected from a pool of patients who required bilateral sinus elevation procedures for posterior implant placement. One of the authors treated the patients between 2003 and 2004 in the Clalit Sick Fund Israel Clinics, Tel-Aviv, Israel. All patients selected a treatment plan requiring maxillary sinus elevation after alternative treatment plans were discussed.

The study included patients who demanded fixed restorative appliances in the posterior maxilla and presented with atrophic posterior maxillae with less than 5 mm of residual alveolar bone height. Participants signed an informed consent form in which the procedure was explained in detail according to the institutional review board of Clalit Sick Fund Israel.

A staged approach was carried out in all 10 sites. Sinus elevation grafting procedures were followed by implant placement 9 months later. Mineralized FDBA (250 to 710  $\mu\text{m}$ ; Oragraft, LifeNet) was applied to one side, and DBBM (particle size, 1 to 2 mm; Bio-Oss Spongiosa, Geistlich) was used for sinus augmentation of the contralateral side.

Exclusion criteria consisted of chronic steroid therapy, uncontrolled diabetes, cardiovascular disease, past head and neck irradiation, maxillary sinus cysts, active chronic sinusitis, smoking more than five cigarettes per day during the study period, and inability to perform proper oral hygiene procedures.

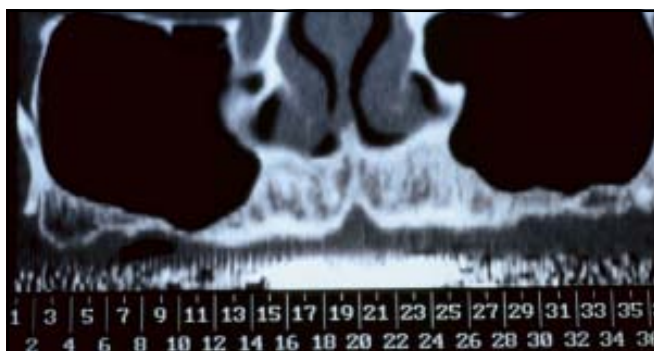
A thorough presurgical evaluation was carried out, including a

full-mouth periodontal chart, occlusal analysis, study of the mounted casts, and diagnostic wax-up, as well as initial periodontal therapy including oral hygiene instructions and training and scaling and root planing where indicated. This was followed by additional periodontal therapy to reduce periodontal probing depth and bleeding on probing until a Plaque Index<sup>18</sup> of less than 10% was achieved. Bone height in both sinus floors was determined using presurgical computed tomography (CT) (Fig 1a).

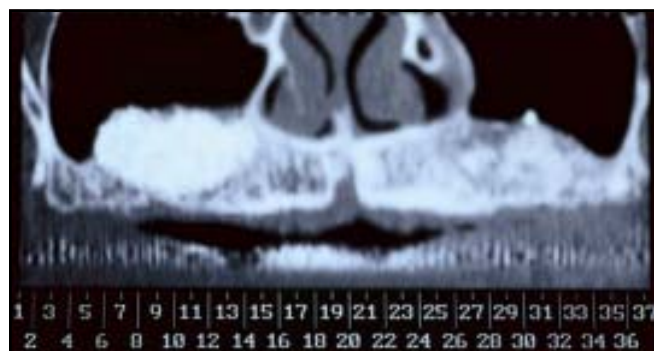
## Surgical technique

The surgical procedures followed the technique described by Smiler and Holmes,<sup>5</sup> with minor deviations as described by Kolerman et al.<sup>19</sup> Briefly, a bioabsorbable porcine collagen barrier membrane (Bio-Gide, Geistlich) was placed under the sinus membrane and adapted to make contact with the peripheral bony walls. The established void was filled with either bovine bone (Bio-Oss Spongiosa) or allograft (Oragraft) in the left or the right sinus, determined by tossing a coin. An outer similar occlusive barrier membrane (Bio-Gide) was applied to cover the entire external augmented site. After achieving primary soft tissue closure, the provisional removable appliance was relieved or readapted prior to reinsertion.

Postoperatively, systemic antibiotics (augmentin 875 mg bid) were administered for 1 week, and 4 mg dexamethasone was prescribed for



**Fig 1a** Patient 1. Baseline CT scan showing bilateral sinus pneumatization.



**Fig 1b** Nine-month post-bilateral augmentation CT scan.

2 successive days to reduce swelling. A generic nasal decongestant (Sinaf, Taro Pharmaceutical) was recommended. A 0.2% chlorhexidine gluconate solution was used bid for 2 weeks until suture removal. The exact location of the grafted/regenerated sites was examined at 9 months using CT scans (Figs 1b, 2a, and 2b). Surgical stents were used to guide 3-mm-diameter trephine burs (Biomet 3i) to the final depth of each osteotomy. Cylindric cores (2 mm in diameter, 10 to 15 mm in length) were harvested and fixed in 10% neutral buffered formalin for 76 hours, decalcified in 5% formic acid for 14 days, and embedded in paraffin. Blocks were cut to 5- $\mu$ m-thick slides and stained with hematoxylin-eosin (h&e) and Mallory. Each core biopsy was composed of native bone and regenerated tissue. The specimen site was enlarged to a suitable osteotomy for implant placement. Clinical follow-up was scheduled monthly. At 6 months, all implants appeared clinically and radiographically osseointegrated, according to the criteria for implant success proposed by Albrektsson et al.<sup>20</sup>

### Histomorphometric analysis

A trained observer used a microscope millimeter eyepiece grid at 100 $\times$  magnification for histomorphometric measurements. Each grid was composed of 121 intersections, and each slide was measured at 10 different sites (total number of analysis points, 1,210 per slide). Measurements were taken from only the core zone including newly formed tissue. Pristine bone was identified according to a lack of graft material (acellular bone) and was excluded from the data analyzed. Graft particles were identified by their typical structure and by the presence of empty lacunae. Histomorphometric analysis included bone graft particles, newly formed bone, and connective tissue. The percentage of each of the three components in each slide was evaluated by counting the presence of each tissue type on every grid intersection. The total count of all points of each tissue type was divided by 1,210. This represents the relative percentage area of each component involved

in the total area of the newly regenerated tissue.

The Student *t* and Pearson correlation tests, based on the overall percentage of each compartment in each slide, were used for statistical analysis. Age, sex, and graft material were the independent variables, while soft tissue, residual graft, and new bone served as dependent variables.

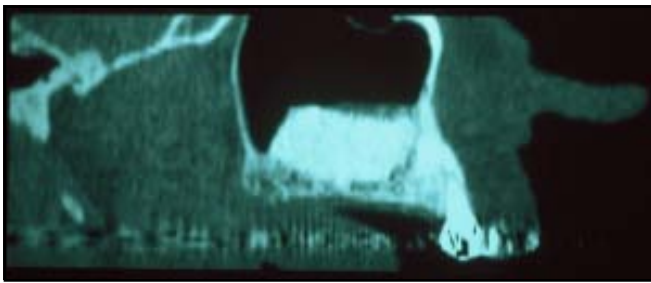
## Results

All 10 augmented sinuses provided 12 mm or more available bone for implant placement. Each augmented sinus provided at least one intact core 2 mm in width and 10 to 15 mm in length.

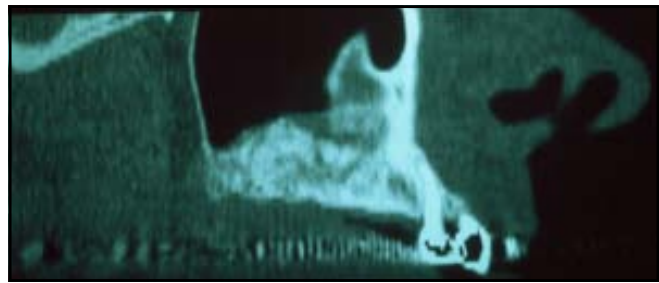
### Histology

#### Oragraft

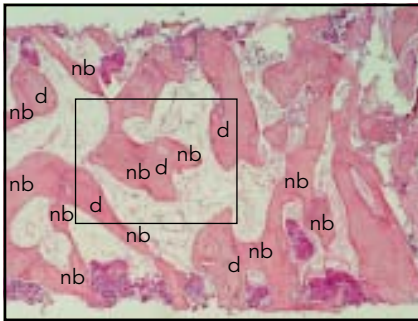
Newly formed bone was evident in all augmented sites; allograft particles were observed surrounded by newly formed bone with close contact between the two, connective



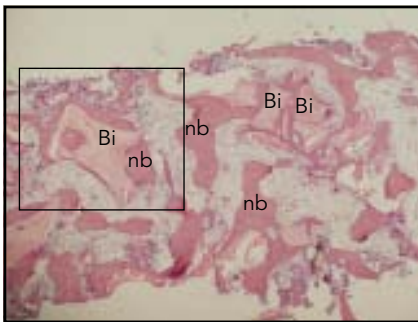
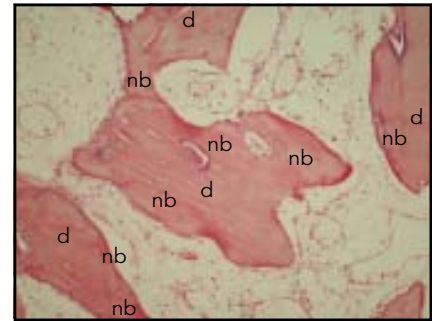
**Fig 2a** Patient 2. Right sinus augmented with Bio-Oss.



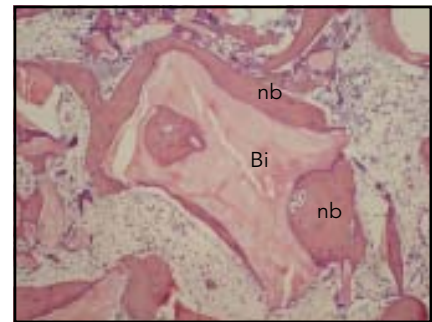
**Fig 2b** Left sinus augmented with Oragraft.



**Figs 2c and 2d** Histologic sections at 9 months. FDDB (Oragraft) particles (d, empty lacuna) were observed close to newly formed bone (nb, osteocyte in lacuna) and in contact with connective tissue (h&e, original magnification [left]  $\times 40$  and [right]  $\times 100$ ).



**Figs 2e and 2f** Histologic sections at 9 months. Bio-Oss particles (Bi) were observed close to newly formed bone (nb, osteocyte in lacuna) and in contact with connective tissue (h&e, original magnification [left]  $\times 40$  and [right]  $\times 100$ ).



tissue, or both (Figs 2c and 2d). Osteoblasts and osteoid tissue were observed around the FDDB particles. There was no evidence of acute inflammatory infiltrate.

**Bio-Oss**

Bio-Oss particles were distributed and interconnected by bony bridges (Figs 2e and 2f). Together with the newly formed bone, the granules presented a dense network of hard tissue. The intertrabecular

marrow consisted of fibrous tissue and vascularized marrow spaces. The pristine bone area consisted of low-density spongiosa and well-vascularized bone marrow.

*Histomorphometry*

New bone content ranged between 23% and 50% (mean, 31.8%) in Oragraft specimens compared with 20% to 34% (mean, 27.2%)

in the Bio-Oss specimens (Tables 1 and 2). The mean percentage of residual graft was lower in Oragraft specimens (21.5%) than in Bio-Oss specimens (24.2%). The mean percentage of marrow and connective tissue was 46.7% (Oragraft) and 48.6% (Bio-Oss). Statistical comparison between Bio-Oss and Oragraft specimens did not show any difference in new bone formation, residual graft materials, or connective tissue compartments.

Material	Patient				
	1	2	3	4	5
<b>% New bone</b>					
DBBM	31.0	20.0	22.0	34.0	27.0
FDBA	28.5	32.0	23.0	26.0	50.0
<b>% Residual graft</b>					
DBBM	24.0	35.0	29.0	18.0	21.0
FDBA	23.5	18.0	23.5	34.0	9.0
<b>% Connective tissue</b>					
DBBM	45.0	45.0	49.0	48.0	52.0
FDBA	48.0	50.0	53.5	40.0	41.0

DBBM = deproteinized bovine bone mineral (Bio-Oss); FDBA = freeze-dried bone allograft (Oragraft).

Material	Mean ± SD	SEM
<b>% New bone</b>		
DBBM	27.2000 ± 5.3572	2.3958
FDBA	31.8060 ± 10.8404	4.8480
<b>% Residual graft</b>		
DBBM	24.2000 ± 4.8683	2.1772
FDBA	21.5040 ± 9.0272	4.0371
<b>% Connective graft</b>		
DBBM	48.6000 ± 2.5100	1.1225
FDBA	46.6880 ± 5.6742	2.5376

SD = standard deviation; SEM = standard error of the mean; DBBM = deproteinized bovine bone mineral; FDBA = freeze-dried bone allograft.

## Discussion

There are only a few randomized controlled clinical trials that com-

pare FDBA and DBBM in split-mouth studies.<sup>15,17</sup> The present study incorporated a bilateral sinus protocol using the lateral wall tech-

nique with double use of collagen membrane, ie, internal (beneath the sinus membrane) and external (covering the lateral window).

The objective of this study was to evaluate the healing response to two mineralized materials used for sinus elevation procedures. It has been assumed that the difference between filling materials used in sinus elevation procedures may modulate the quality and quantity of newly formed bone. Both materials showed graft particles in direct contact with new bone. In the present study, bone regeneration in the Oragraft sites (31.8%) was comparable with that in Bio-Oss sites (27.2%), although those results are based on only five patients. The results compare with those published by Froum et al<sup>15</sup> using a mineralized solvent dehydrated cancellous bone allograft (Puros, Zimmer) (new bone, 28.3%). In that study, a significantly lower percentage of new bone (12.4%) was found in the contralateral Bio-Oss-grafted side, which may be explained in part by the shorter time period between the surgical procedure and biopsy harvesting (26 to 32 weeks compared with 36 weeks in the present study). Noubbissi et al<sup>17</sup> reported faster bone formation in sinuses augmented with Puros compared to sinuses augmented with a composite graft of DFDBA and DBBM (Bio-Oss). Furthermore, they recorded a similar percentage of newly formed bone for Puros (40.3%) and the composite graft (38.8%). The cores obtained 10 months after sinus elevation were nondecalcified sections stained with Stevenel blue and Van Gieson picro fuchsin.<sup>17</sup>

The results of the present study regarding FDBA were lower than

those described by Cammack et al,<sup>14</sup> who compared FDBA (41.1%) and DFDBA (36%) in sinus elevation procedures. In that study, histomorphometric analysis included the sum of a set of polygons traced on the sample, which allowed the software to calculate a set of areas (ie, new bone, residual graft particles, and soft tissue) as part of the total area of the sample. The present study used the point-counting technique as described previously. The variance in the results between the two studies may be attributed partly to the different morphometric techniques used. Furthermore, in the former study, samples were harvested 11 months postsurgery in the FDBA group, which could have contributed to the additional amount of newly formed bone. Although authors consider DFDBA to be osteoconductive, Valentini and Abensur,<sup>13</sup> who used a composite graft of DFDBA and bovine bone xenograft (DBBM) in 20 patients, claim that new bone was in contact with the DBBM particles, while the DFDBA particles were surrounded by connective tissue. In the present study, a mineralized material was used because of the low osteoconductive value of DFDBA.<sup>13,16</sup> The studies in which FDBA was used to augment the sinus floor showed the material to be osteoconductive. For these reasons, this study compared FDBA with DBBM, the gold standard nonautogenous material in sinus elevation. The efficacy of DBBM as a graft material for sinus floor elevation is well documented.<sup>8,13,17,21</sup> Newly formed bone

increased from 21.1% to 27.6% from 6 to 12 months using DBBM, and the graft particles decreased from 39.8% to 27%.<sup>13</sup> Active remodeling and osteoclastic activity and replacement of graft particles with vital bone were observed. The increased quantity of newly formed bone with time occurs mainly in the connective tissue compartment. Lack of Bio-Oss particle breakdown has been supported,<sup>22,23</sup> while others have reported signs of resorption and osteoclasts present around Bio-Oss particles.<sup>24</sup>

DBBM was compared with a nonceramic resorbable hydroxyapatite graft, particles were observed in all specimens surrounded by newly formed bone in direct contact with the particles or by connective tissue from bone marrow. Percent new bone was higher in the DBBM-grafted sinuses (42.1%) compared with those grafted with nonceramic resorbable hydroxyapatite (33.3%). The fraction of graft particles in both cases was similar (24.7% and 24.6%).<sup>8</sup>

Piattelli et al<sup>25</sup> reported 30% bone, 30% residual graft particles, and 40% bone marrow in 20 human sinuses 6 months after the sinus augmentation procedure, in which Bio-Oss was used as a filler material. These results are similar to the present study 9 months after sinus floor elevation when DBBM was used (27.2% vital bone).

Although the advantages of using a barrier membrane over the lateral bony window are well documented,<sup>21,26</sup> others claim no additional benefit.<sup>27</sup> However, the use of an internal collagen membrane

beneath the sinus membrane is not fully documented. In the present study, collagen membranes were routinely placed beneath the reflected sinus membrane, although the membrane remained intact in all procedures. Care was taken to not cover the peripheral bony walls. The role of sinus membrane perforation regarding implant success is still controversial.<sup>28-30</sup> However, blood clot formation and subsequent bone growth should be more predictable using a second biologic barrier. A perforated sinus membrane carries the risk of infection by exposing the healing site to the external respiratory system. The use of an internal membrane offers an additional biologic barrier that may help prevent the passage of graft particles and bacterial contamination to and from the sinus cavity resulting from potential small tears. Still, a recent study<sup>30</sup> concluded that perforations of the sinus membrane corrected with a collagen membrane did not compromise the osseointegration of dental implants placed in the augmented maxillary sinus.

## Conclusion

Within the limits of the present study, it may be concluded that mineralized ground cortical bone allograft (Oragraft) is comparable to DBBM xenograft (Bio-Oss) for sinus augmentation procedures. A larger study may lead to more definitive conclusions. The use of an internal collagen membrane for sinus eleva-

tion procedures on a routine basis may need further investigation.

## Acknowledgments

The authors wish to thank Mrs Hana Vered for the histologic preparations and Dr Marilena Vered for her help with the histomorphometric measurements. The study was carried out in the Alpha Omega Research Laboratories at the Maurice and Gabriela Goldschleger School of Dental Medicine, Tel Aviv University. The study was supported by the Gerald Niznick Chair of Implantology.

## References

1. Pecora GE, De Leonardis D, Della Rocca C, Cornelini R, Cortesini C. Short-term healing following the use of calcium sulfate as a grafting material for sinus augmentation: A clinical report. *Int J Oral Maxillofac Implants* 1998;13:866-873.
2. Wallace SS, Froum SJ. Effect of maxillary sinus augmentation on the survival of endosseous dental implants. A systemic review. *Ann Periodontol* 2003;8:328-343.
3. Tatum OH. Maxillary sinus grafting for endosseous implants. Presented at the annual meeting of the Alabama Implant Study Group, Birmingham, Alabama, April 1977.
4. Boyne PJ, James RA. Grafting the maxillary sinus floor with autogenous marrow and bone. *J Oral Surg* 1980;38:613-616.
5. Smiler DG, Holmes RE. Sinus lift procedure using porous hydroxyapatite: A preliminary report. *J Oral Implantol* 1987;13:239-253.
6. Misch CE. Maxillary sinus augmentation for endosteal implants: Organized alternative treatment plans. *Int J Oral Implantol* 1987;4:49-58.
7. Wagner JR. A 3 1/2 year clinical evaluation of resorbable hydroxylapatite Osteo-Gen (HA Resorb) used for sinus lift augmentations in conjunction with the insertion of endosseous implants. *J Oral Implantol* 1991;17:152-164.
8. Artzi Z, Nemcovsky CE, Tal H, Dayan D. Histopathological morphometric evaluation of 2 different hydroxyapatite-bone derivatives in sinus augmentation procedures: A comparative study in humans. *J Periodontol* 2001;72:911-920.
9. Artzi Z, Tal H, Dayan D. Porous bovine bone mineral in healing of human extraction sockets: 2. Histochemical observations at 9 months. *J Periodontol* 2001;72:152-159.
10. Groeneveld EHV, van der Bergh JPA, Holzmans P, ten Bruggenkate CM, Tuinzing DB, Burger EH. Histological observations of a bilateral maxillary sinus floor elevation 6 and 12 months after grafting with osteogenic protein-1 device. *J Clin Periodontol* 1999;26:841-846.
11. Groeneveld EHV, van der Bergh JPA, Holzmans P, ten Bruggenkate CM, Tuinzing DB, Burger EH. Histomorphometrical analysis of bone formed in human maxillary sinus floor elevations grafted with OP-1 device, demineralized bone matrix or autogenous bone. Comparison with non-grafted sites in series of case reports. *Clin Oral Implants Res* 1999;10:499-509.
12. Jensen SS, Aaboe M, Pinholt EM, Hjorting-Hansen E, Melsen F, Ruyter IE. Tissue reaction and material characteristics of four bone substitutes. *Int J Oral Maxillofac Implants* 1996;11:55-66.
13. Valentini P, Abensur D. Maxillary sinus floor elevation for implant placement with demineralized freeze-dried bone and bovine bone (Bio-Oss): A clinical study of 20 patients. *Int J Periodontics Restorative Dent* 1997;17:232-241.
14. Cammack GV 2nd, Nevins M, Clem DS 3rd, Hatch JP, Mellonig JT. Histologic evaluation of mineralized and demineralized freeze-dried bone allograft for ridge and sinus augmentations. *Int J Periodontics Restorative Dent* 2005;25:231-237.
15. Froum SJ, Wallace SS, Elian N, Cho SC, Tarnow DP. Comparison of mineralized cancellous bone allograft (Puros) and anorganic bovine bone matrix (Bio-Oss) for sinus augmentation: Histomorphometry at 26 to 32 weeks after grafting. *Int J Periodontics Restorative Dent* 2006;26:543-551.
16. Jensen OT, Shulman LB, Block MS, Iacono VJ. Report of the Sinus Consensus Conference of 1996. *Int J Oral Maxillofac Implants* 1998;13(suppl):11-45.

17. Noubissi SS, Lazada JL, Boyne PJ, et al. Clinical, histologic, and histomorphometric evaluation of mineralized solvent-dehydrated bone allograft (Puros) in human maxillary sinus grafts. *J Oral Implantol* 2005;31:171–178.
18. Löe H. The Gingival Index, the Plaque Index and the Retention Index System. *J Periodontol* 1967;38(suppl):610–616.
19. Kolerman R, Tal H, Moses O. Histomorphometric analysis of newly formed bone after maxillary sinus floor augmentation using ground cortical bone allograft and internal collagen membrane. *J Periodontol* 2008;79:2104–2111.
20. Albrektsson T, Zarb G, Worthington P, Eriksson AR. The long-term efficacy of currently used dental implants: A review and proposed criteria of success. *Int J Oral Maxillofac Implants* 1986;1:11–25.
21. Tawil G, Mawla M. Sinus floor elevation using a bovine bone mineral (Bio-Oss) with or without the concomitant use of a bilayered collagen barrier (Bio-Gide): A clinical report of immediate and delayed implant placement. *Int J Oral Maxillofac Implants* 2001;16:713–721.
22. Hallman M, Cederlund A, Lindskog S, Lundgren S, Sennerby L. A clinical histologic study of bovine hydroxyapatite in combination with autogenous bone and fibrin glue for maxillary sinus floor augmentation. Results after 6 to 8 months of healing. *Clin Oral Implants Res* 2001;12:135–143.
23. Merx MAW, Maltha JC, Stoeltinga PJW. Assessment of the value of anorganic bone additives in sinus floor augmentation: A review of clinical reports. *Int J Oral Maxillofac Surg* 2003;32:1–6.
24. Hürzeler MB, Quiñones CR, Kirsch A, et al. Maxillary sinus augmentation using different grafting materials and dental implants in monkeys. Part I. Evaluation of anorganic bovine-derived bone matrix. *Clin Oral Implants Res* 1997;8:476–486.
25. Piattelli M, Favero GA, Scarano A, Orsini G, Piattelli A. Bone reactions to anorganic bovine bone (Bio-Oss) used in sinus augmentation procedures: A histologic long-term report of 20 cases in humans. *Int J Oral Maxillofac Implants* 1999;14:835–840.
26. Tarnow DP, Wallace SS, Froum SJ, Rohrer MD, Cho SC. Histologic and clinical comparison of bilateral sinus floor elevations with and without barrier membrane placement in 12 patients: Part 3 of an ongoing prospective study. *Int J Periodontics Restorative Dent* 2000;20:117–125.
27. Fugazzotto PA, Vlassis J. Report of 1633 implants in 814 augmented sinus areas in function for up to 180 months. *Implant Dent* 2007;16:369–378.
28. Avera SP, Stampely WA, McAllister BS. Histologic and clinical observations of resorbable and nonresorbable barrier membranes used in maxillary sinus graft containment. *Int J Oral Maxillofac Implants* 1997;12:88–94.
29. van den Bergh JPA, ten Bruggenkate CM, Disch FJM, Tuinzing DB. Anatomical aspects of sinus floor elevations. *Clin Oral Implants Res* 2000;11:256–265.
30. Karabuda C, Arisan V, Özyuvaci H. Effects of sinus membrane perforations on the success of dental implants placed in the augmented sinus. *J Periodontol* 2006;77:1991–1997.