Evaluation of Volumetric Changes of Augmented Maxillary Sinus With Different Bone Grafting Biomaterials

B. Alper Gultekin, DDS, PhD, Erol Cansiz, DDS, PhD,† Oguz Borahan, DDS, PhD,‡ Carlo Mangano, MD, DDS,§ Roni Kolerman, DMD,|| Eitan Mijiritsky, DMD,¶ and Serdar Yalcin, DDS, PhD#*

Abstract: Extensive alveolar bone resorption because of pneumatized maxillary sinus is a common problem that limits dental implant placement. Maxillary sinus floor augmentation (MSFA) is an accepted treatment protocol that provides sufficient bone volume. The aim of this study was to evaluate the percentage of graft volume reduction following MSFA using cone beam computed tomography. In this retrospective study, cone beam computed tomography scans of MSFA were measured to evaluate the volume of the grafted sinus with deproteinized bovine bone (DBB), mineralized allograft (MA), or a mixture of MA and demineralized allograft as a composite. The volumetric changes in sinus augmentation between 2 weeks (T-I) and 6 months (T-II) after operation were analyzed. Thirty-nine patients were included in this study. The average percent volume reduction was $8.14 \pm 3.76\%$, $19.38 \pm 9.22\%$, and $24.66 \pm 4.68\%$ for DBB, MA, and composite graft, respectively. A significant graft volume reduction was found between T-I and T-II for all groups ($P < 0.01$). The DBB group showed the least volume reduction ($P < 0.01$). Biomaterials can influence the bone graft volume change before implant placement. Deproteinized bovine bone may offer greater volume stability during healing than mineralized and composite allografts.

Key Words: Bone substitutes, cone beam computed tomography, sinus floor augmentation, volume change

The edentulous posterior maxilla is one of the most challenging locations for implant placement owing to severe resorption of the alveolar ridge after tooth loss, pneumatized maxillary sinus, and low quality of bone.[1,2] An ideal biomaterial for maxillary sinus floor augmentation (MSFA) should have the ability to form new bone and must be balanced with the speed of resorption.[1–4] Autogenous bone is the gold standard for augmentations because of its osteogenic potential.[1,5] Its availability, however, is limited and its use is associated with donor-site morbidity.[1,5,6]

In this study, it was focused on 3 different biomaterials: deproteinized bovine bone (DBB), mineralized allograft (MA), and demineralized allograft (DA). Deproteinized bovine bone is osteoconductive and has an interconnecting pore system that serves as a scaffold for the migration of osteogenic cells; the anorganic bone substance has a microscopic structure similar to that of natural cancellous bone.[5,7,8] Mineralized allograft provides stability and space by maintaining its physical properties during the bone remodeling phase.[3,6] Demineralized allograft contains bone morphogenic proteins and stimulates osteoinduction. Demineralized allograft, however, is highly biodegradable and has less compressive strength than DBB and MA.[6,9]

During healing, graft volume stability is considered as an important factor for the success of the procedure, especially in the 2-stage MSFA approach. Cone beam computed tomography (CBCT) is a useful radiologic method to measure the amount of grafted bone before implant placement and to evaluate the three-dimensional size of the grafted region following MSFA.[10–12]

The aim of the current study was to compare the grafted volume on repeated CBCT scans from patients who underwent an MSFA with DBB, MA, or a mixture of MA and DA as a composite.

MATERIALS AND METHODS

Study Design

In this retrospective study, CBCT scans of maxillary sinuses in patients who needed 2-stage MSFA augmentation with a residual bone height of <5 mm in the posterior maxilla for implant placement were collected from the Oral Implantology Department database between January 2010 and January 2013. The study criterion was availability to undergo CBCT examination soon after MSFA. The inclusion criteria were patients who underwent either a uni- or bilateral MSFA using DBB (Bio-Oss; Geistlich Pharma AG, Wolhusen, Switzerland) with a 0.25 to 1 mm particle size; MA (MinerOss; BioHorizons, Birmingham, AL) with a 0.6 to 1.25 mm particle size; or MA mixed with DA (Grafton; BioHorizons) in a putty form as a composite (50% MA/50% DA). The exclusion criteria were smoking (≥10 cigarettes/day), maxillary sinus pathology, and chronic sinusitis, systemic disease that would contraindicate oral surgery, chronic periodontitis in the remaining teeth, and large sinus membrane perforation that could not be repaired during MSFA. The study protocol was approved according to the Declaration of Helsinki by the Ethical Committee of Istanbul University, Turkey (Approval no: 2015/26). Written informed consent was acquired from all patients.

Surgical Methods

All periodontal and endodontal pathologies were treated before the operations. All surgical procedures were carried out under local anesthesia (Ultracain D-S Forte; Sanofi-Aventis, Istanbul, Turkey). After crestal and vertical incisions, a full-thickness flap was raised, and an access window was made by drilling the buccal sinus wall with a dental carbide bur and, then, with a wide-diameter diamond bur in a high-speed handpiece under constant sterile saline irrigation. In thin walls, piezosurgery was also used for window preparation. The intact sinus membrane was elevated. If any perforation of the maxillary sinus membrane occurred, perforation was repaired using a collagen resorbable membrane (Mem-Lok; Collagen Matrix, Franklin Lakes, NJ). According to the experimental group,

From the *Department of Oral Implantology; †Department of Oral and Maxillofacial Surgery, Istanbul University Faculty of Dentistry; ‡Department of Oral and Maxillofacial Radiology, Marmara University Faculty of Dentistry, Istanbul, Turkey; §Department of Oral Medicine and Biotechnological Sciences, University of Chieti, Chieti, Italy; ||Department of Periodontics; ¶Department of Oral Rehabilitation, The Maurice and Gabriela Goldschleger School of Dental Medicine, Tel Aviv University, Israel; and #Department of Oral Implantology, Istanbul University Faculty of Dentistry, Istanbul, Turkey.
Received May 29, 2015.
Accepted for publication November 16, 2015.
Address correspondence and reprint requests to B. Alper Gultekin, Department of Oral Implantology, Istanbul University Faculty of Dentistry, Istanbul 34390, Turkey; E-mail: alpergultekin@hotmail.com
The authors report no conflicts of interest.
Copyright © 2016 by Mutaz B. Habal, MD
ISSN: 1049-2275
DOI: 10.1097/SCS.0000000000002393

Copyright © 2016 Mutaz B. Habal, MD. Unauthorized reproduction of this article is prohibited.

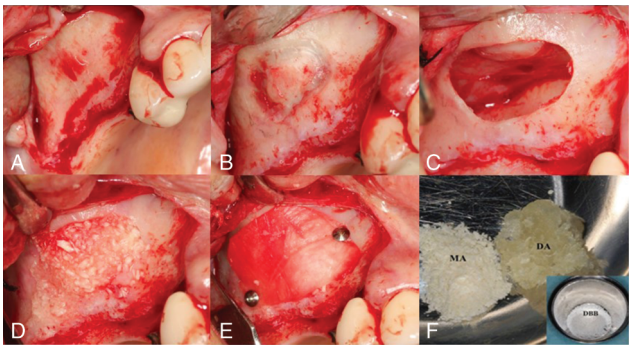

FIGURE 1. A, Midcrestal and vertical buccal incisions were made along the residual alveolar bone. B, A diamond bur was used to open a window into the buccal sinus wall. C, The bone at the center of the access window was gently fractured and the intact sinus membrane was elevated. D, Patients requiring maxillary sinus floor augmentation underwent grafting procedures with deproteinized bovine bone, MA, or MA mixed with DA as a composite (50% MA/50% DA). E, A resorbable collagen barrier membrane was placed and tacked on the buccal wall of the maxillary sinus. F, Deproteinized bovine bone, MA, and DA were hydrated with saline before application. DA, demineralized allograft; MA, mineralized allograft.

the graft was gently packed until it filled the entire cavity between the sinus floor and the sinus membrane. A resorbable collagen barrier membrane (Mem-Lok) was tacked (Pinfix; Sedenta, Istanbul, Turkey) on the buccal wall of the sinus to prevent displacement of the graft and invasion by soft tissue (Fig. 1). The mucosal flap was replaced with 4–0 silk (Dogsan Surgical Sutures, Trabzon, Turkey) for primary closure.

Postsurgical medications were prescribed, including antibiotics starting on the day of surgery and the following 7 days (1000 mg amoxicillin and clavulanic acid, twice daily), analgesics (600 mg ibuprofen to be taken as needed every 6 hours), and 0.2% chlorhexidine mouthwash twice daily for 2 weeks starting on the day after the operation. Dexamethasone (4 mg daily) was administered for 2 days to minimize edema. The sutures were removed 10 days after the surgery. Bone grafts were allowed to heal 6 months before root-form roughed surface implants were placed. The implants were then allowed to acquire secondary stability a further 3 to 4 months before prosthodontic rehabilitation. All patients received cement-retained fixed prosthetic restorations with porcelain fused to metal crowns or bridges. Clinical examination of the implants placed in the grafted sinus was performed according to survival rate criteria.[13]

Radiographic Analysis

Cone beam computed tomography imaging was performed before the operation (T-0) and within 2 weeks (T-I) and 6 months after MSFA (T-II). The scans were evaluated using the i-CAT 3D Imaging System (Imaging Sciences International Inc, Hatfield, PA) with a field of view of 13 × 8 cm and a voxel size of 0.25. The digital volumetric calculation methodology was described in earlier publications.[12,14] The data obtained from the CBCT images of upper jaw were transferred to a network computer workstation, where the volumetric changes of the graft were analyzed using MIMICS 14.0 software (Materialise Europe, Leuven, Belgium). Sinus bone grafts were reformed in three dimensions (in mm^3) to assess the volume changes at 2 reference time points (T-I and T-II) with 3 different graft materials (DBB, MA, and composite) after MSFA (Fig. 2). The preoperative residual bone height (H-0) and width (W-0) of the alveolar ridge was measured using iCat software (Imaging Sciences International Inc) at the point near the planned implant insertion location at T-0. Ridge width was calculated at a level corresponding

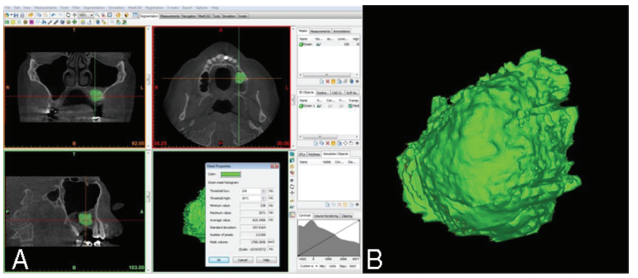

FIGURE 2. A, Digital reconstruction was accomplished by selecting the grafted volume and was carried out manually with a threshold value according to the gray values of native bone, grafted bone, soft tissue, and sinus cavity expressed on the software program. B, The selected graft region was demarcated in different colors and the volume of the graft was calculated in mm^3.

to midheight. A single value of ridge height and width was contemplated for each grafted site.

Statistical Analysis

The power analysis for the comparison of volume reduction between groups resulted in power = 0.80, $\beta = 0.20$, and $\alpha = 0.05$ (in accordance with the reference related to the parameter of volume reduction of grafted sinus parameter, $\Delta = 0.45$ and standard deviation = 0.47). Based on this calculation, the necessary sample size was 11 patients/group. Changes in grafted bone volume over time were analyzed statistically using IBM SPSS Statistics 22 software (IBM SPSS, Armonk, NY). The Kolmogorov-Smirnov test was used to test the normality of the data distribution. Quantitative data were analyzed using one-way analysis of variance and Tukey honest significant difference test was used for the determination of group causing differences. Within-group comparisons were performed with the paired-sample *t*-test for normally distributed data. The level of statistical significance was set at $P < 0.05$.

RESULTS

Overall, this study examined 42 patients, each of whom received DBB, MA, or composite grafts for MSFA. In 1 case in the DBB group, bilateral augmentation was performed. Three out of 42 patients were excluded from the analysis because demarcation of the border between the graft and maxillary sinus walls became indistinct at follow-up (T-II), thus hindering the quality of the measurements. Minor perforation of the sinus membrane occurred in 3 cases (2 DBB, 1 MA), all of which were closed successfully with collagen membrane. In 1 case, a nosebleed occurred after surgery; however, the graft was intact. Bleeding was controlled by using 4.5 cm standard nasal dressing (Merocel Nasal Dressing; Meditas, Istanbul, Turkey) within 1 hour. No further surgical complications were observed during follow-up. In total, 39 patients (age range, 28–74 years) fulfilling the criteria (22 women with a mean age of 53.5 ± 10.62 years and 17 men with a mean age of 50.23 ± 11.44 years) were included in this study. Of these augmentations, 14 received DBB, 14 received MA, and 12 received composite. One-way analysis of variance test results revealed no significant differences in the mean residual bone height and width between DBB, MA, and composite groups before the surgery ($P > 0.05$; Table 1). The mean graft volume reduction rate was 17.03 ± 9.35%. A significant graft volume reduction was found between T-I and T-II for all groups ($P < 0.01$ by paired-sample *t*-test; Table 2). In patients receiving DBB, MA, and composite grafts, the average percent volume reduction was 8.14 ± 3.76%, 19.38 ± 9.22%, and 24.66 ± 4.68%, respectively (Table 2). A comparative analysis revealed significant differences between the DBB

Copyright © 2016 Mutaz B. Habal, MD. Unauthorized reproduction of this article is prohibited.

TABLE 1. The Mean Residual Bone Height and Width at the Planned Implant Sites Before the Surgery

	Residual Bone Height (mm) Mean ± SD	Residual Bone Width (mm) Mean ± SD
DBB	3.24 ± 0.83	7.54 ± 1.36
MA	3.37 ± 0.65	7.32 ± 1.00
Composite	3.75 ± 0.65	7.61 ± 0.95
*P	0.194	0.778

Deproteinized bovine bone; composite, mineralized allograft mixed with demineralized allograft as a composite; mineralized allograft.
DBB, deproteinized bovine bone; MA, mineralized allograft.
* One-way ANOVA.

and other groups 6 months after MSFA ($P < 0.05$ by Tukey honest significant difference). The DBB group showed the least reduction in volume, and this reduction was significantly lower than the other 2 groups ($P < 0.01$; Fig. 3). There was no significant difference in volume reduction rate between the MA and composite groups ($P > 0.05$; Fig. 3). A total of 77 dental implants were placed in the grafted sinuses successfully. The manufacturers of the implants used were BioHorizons (N = 50, Birmingham, AL), Biomet 3i (N = 15, Palm Beach, FL), and Nobel Biocare AB (N = 12, Göteborg, Sweden). No implants were lost during the 2-year follow-up. The survival rate was 100% according to Albrektsson criteria.

DISCUSSION

The aim of this study was to evaluate the volumetric changes in grafted sites following 2-stage MSFA with DBB, MA, and composite biomaterials. Biomechanically, an extended maxillary sinus floor can decrease stress at the bone-implant interface in MSFA sites and prolong the survival rate of dental implants.[15] Even though the surgical technique has not changed markedly for lateral MSFA, optimum bone graft material selection has not been resolved by clinicians. Knowledge of volumetric changes after MSFA can assist in guiding appropriate selection of the graft material.[16,17] In the current study, a significant volumetric reduction was measured in all groups. The resorption rate of the inserted grafts was 8.14 ± 3.76%, 19.38 ± 9.22%, and 24.66 ± 4.68% for DBB, MA, and the composite group, respectively.

In previous studies, DBB particles showed no or limited resorption after MSFA, and even after 11 years, nonresorbed particles can be observed integrated with natural bone.[4,5,18–20] This confirms that

TABLE 2. The Graft Volume Changes at T-I (2 Weeks After Surgery) and T-II (6 Months Postaugmentation) for All Groups

	DBB Mean ± SD	MA Mean ± SD	Composite Mean ± SD	†P
T-I (mm^3)	2456.98 ± 678.05	2828.64 ± 865.23	2145.33 ± 599.5	0.070
T-II (mm^3)	2263.8 ± 678.33	2277.24 ± 727.49	1613.72 ± 446.16	0.018*
Volumetric change rate (%)	8.14 ± 3.76	19.38 ± 9.22	24.66 ± 4.68	0.001**
‡P	<0.001**	<0.001**	<0.001**	

Deproteinized bovine bone; composite, mineralized allograft mixed with demineralized allograft as a composite; mineralized allograft.
DBB, deproteinized bovine bone; MA, mineralized allograft.
† One-way ANOVA.
‡ Paired-sample *t*-test.
* Statistically significant.
** Statistically significant.

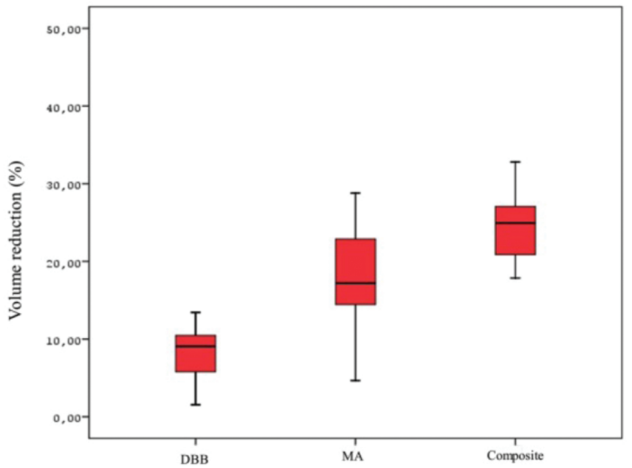

FIGURE 3. Box plot of percent bone-graft volume reduction in the experimental groups (deproteinized bovine bone, mineralized allograft, and composite) after 6 months.

a complete replacement of the graft material by newly formed bone may not be necessary for the success of MSFA.[12] Mazzocco et al[12] reported an average volume contraction of 10% at 8 to 9 months after MSFA using DBB, based on a computerized analysis of CBCT scans. Jensen et al[19] observed that the volume of DBB in minipig maxillary sinuses is reduced by 6% after 3 months of healing. Other reports have shown that the volume of DBB is reduced by 15% to 21% after 6 months of healing.[16] Differences in volumetric reduction rate across studies may arise from many factors, such as surgical technique, compression force during packing of graft material into sinus cavity, initial residual height and width, repneumatization force, contact osteogenesis capacity of residual wall surface area connected to grafting material, and software used.[7,16,17] In the current study, the DBB group had the least volume reduction, with an average 8% volume reduction after healing. Materials with low turnover rates are good scaffolds for natural bone growth during healing, and can withstand repneumatization of the sinus.[12,16,20] The slow resorption of DBB could be an advantage in that it helps in keeping the volumetric stability of MSFA, even during longer healing periods.[7,8,20] In a recent article, it, however, was found that increasing amounts of DBB may cause decreased bone-implant contact rates.[21] Therefore, it is important to consider the biomaterials used for MSFA to optimize the volumetric assessment and histologic level.[16]

The group that received only the MA bone graft exhibited an average reduction rate of 19.38 ± 9.22% during the 6-month follow-up period. The allogenic bone that was used in the current study was composed of cortical and cancellous particles. Mineralized cortical particles with slow resorption rates offer a scaffold, whereas cancellous particles with faster resorption rates may provide a space for ingrowth of bone cells and angiogenesis.[3] Kim et al[14] found an average volume reduction of 19.7% for allogenic bone 6 months after MSFA. This study measured volume reduction in three dimensions. In a clinical case, Gapski et al[22] observed 8.49% graft resorption for allogenic bone (same material as the current study) 6 months after healing using radiographic linear data on CBCT. Although CBCT was used for this study, measuring time-dependent volumetric change linearly may not be reliable and may not reflect a total assessment of biomaterial three-dimensional shrinkage after MSFA.[22] These results are generally in accordance with the current study. The increased rate of volume reduction in the MA group may be the result of mineralized cortical and cancellous chips usage. Throughout the 6 months of the healing process, the cancellous part

© 2016 Mutaz B. Habal, MD
Copyright © 2016 Mutaz B. Habal, MD. Unauthorized reproduction of this article is prohibited.

may undergo some resorption within the sinus, and therefore may hinder the ability to resist forces created by air pressure from respiration. If only cortical chips are used, the extent of the reduction may be diminished, because of the high resistance to compression during surgery and repneumatization after operation.

In the current study, the highest volumetric reduction was observed in the composite group. Nevertheless, the difference between MA and the composite was not statistically significant. The DA grafts in this study had high substitution rates. In the current study, DBB and MA showed osteoconductive properties only. Demineralized allograft consists of bone organic matrix that stimulates osteoinduction, resulting in excellent osteoinductive ability.[9] One possible explanation for good incorporation with the preexisting bone may be that the DA composite is resorbed and replaced with new bone during healing.[9] The separation of the border between the graft and the maxillary sinus walls became indistinct. Deproteinized bovine bone grafted sinuses were easily recognizable from natural bone walls, with distinct threshold values during volumetric measurements even after 6 months of healing. Nishibori et al[23] found insufficient bone volume and quality for implant placement in patients with DA grafts. Although the composite group showed the highest volume reduction during healing, no complications were observed. The lifted amount of the maxillary sinus was sufficient for primary stability.

Although autogenous bone is considered the gold standard for bone augmentation, with cellular elements necessary for osteogenesis, previous articles reported severe (45%) resorption rates when using autogenous bone grafts.[16] This high-level resorption rate is unpredictable, and may complicate implant placement when autogenous bone was used as a bone graft material in MSFA.[16] In the current study, the mean resorption rate of $17.03 \pm 9.35\%$ was achieved with different biomaterials after 6 months of healing. Biomaterial usage may allow better prediction of volumetric stability, rather than autogenous bone.

No implants were lost during the 2-year follow-up. Beretta et al[24] observed that 0 to 12 months and 37 to 48 months were 2 distinct time points at which implants could fail after MSFA. Failure rate are often increased using a 1-step protocol.[24] In the current study, all implants were placed in a 2-stage approach, as required by the study protocol, regardless of the choice of biomaterial, resulting in significantly different volume reductions. We found that 6 months of healing was adequate to achieve and maintain stability for 2 years in all 3 bone graft groups.

One of the drawbacks of the current study is the lack of histologic and histomorphometrical analysis in the 3 groups after 6 months of healing. Although the healing period progressed without any complications and all tapered implants were well integrated and loaded, we had no data to address the relationship between volumetric reductions and new bone formation rates. Therefore, it would be better to interpret the results of three-dimensional radiography and histology during the selection of optimum bone graft material for MSFA. The current study sheds valuable insight into radiographic biomaterial selection.

Several techniques have been introduced to measure changes of graft materials. Difficulties in evaluating the resorption rate of the grafted bone by two-dimensional techniques can lead to magnification errors.[16] Studies that use three-dimensional data by computed tomography or CBCT could evaluate volumetric changes more accurately than two-dimensional images.[12,14] One important advantage of CBCT over computed tomography is lower radiation dose. For the current study, it could be speculated that CBCT is a reliable and predictable three-dimensional radiographic technique that yields high-quality volumetric measurements after MSFA.

The results of the current study have shown that these biomaterials are statistically proven to influence the bone graft volume change before implant placement. Significant volume reduction of the MSFA site over time was found for all biomaterials. Deproteinized bovine bone may offer greater volume stability over time than mineralized and composite allografts. Cone beam computed tomography is a reliable and predictable three-dimensional radiographic technique that yields high-quality volumetric measurements of the grafted sinus.

ACKNOWLEDGMENTS

The authors thank Nuray Selcuk, DDS, Department of Oral Implantology, Istanbul University Faculty of Dentistry, Istanbul, Turkey, for help with the clinical data collection.

REFERENCES

1. Pjetursson BE, Tan WC, Zwahlen M, et al. A systematic review of the success of sinus floor elevation and survival of implants inserted in combination with sinus floor elevation. *J Clin Periodontol* 2008;35:216–240
2. Boyne PJ, James RA. Grafting the maxillary sinus floor with autogenous marrow and bone. *J Oral Surg* 1980;38:613–616
3. Avila G, Neiva R, Misch CE, et al. Clinical and histological outcomes after the use of a novel allograft for maxillary sinus augmentation: a case series. *Implant Dent* 2010;19:330–341
4. Landi L, Pretel RW Jr, Hakimi NM, et al. Maxillary sinus floor elevation using a combination of DFDBA and bovine-derived porous hydroxyapatite: a preliminary histologic and histomorphometric report. *Int J Periodontics Restorative Dent* 2000;20:574–583
5. Browaeys H, Bouvry P, De Bruyn H. A literature review on biomaterials in sinus augmentation procedures. *Clin Implant Dent Relat Res* 2007;9:166–177
6. Blomqvist JE, Alberius P, Isaksson S, et al. Importance of bone graft quality for implant integration after maxillary sinus reconstruction. *Oral Surg Oral Med Oral Pathol Oral Radiol Endod* 1998;86:268–274
7. Wallace SS, Froum SJ. Effect of maxillary sinus augmentation on the survival of endosseous dental implants. A systematic review. *Ann Periodontol* 2003;8:328–343
8. Chiapasco M, Casentini P, Zaniboni M. Bone augmentation procedures in implant dentistry. *Int J Oral Maxillofac Implants* 2009;24:237–259
9. Won YH, Kim SG, Oh JS, et al. Clinical evaluation of demineralized bone allograft for sinus lifts in humans: a clinical and histologic study. *Implant Dent* 2011;20:460–464
10. Dasmah A, Thor A, Ekestubbe A, et al. Particulate vs. block bone grafts: three-dimensional changes in graft volume after reconstruction of the atrophic maxilla, a 2-year radiographic follow-up. *J Craniomaxillofac Surg* 2012;40:654–659
11. Reddy MS, Mayfield-Donahoo T, Vanderven FJ, et al. A comparison of the diagnostic advantages of panoramic radiography and computed tomography scanning for placement of root form dental implants. *Clin Oral Implants Res* 1994;5:229–238
12. Mazzocco F, Lops D, Gobbato L, et al. Three-dimensional volume change of grafted bone in the maxillary sinus. *Int J Oral Maxillofac Implants* 2014;29:178–184
13. Albrekttson T, Zarb G, Worthington P, et al. The long-term efficacy of currently used dental implants: a review and proposed criteria of success. *Int J Oral Maxillofac Implants* 1986;1:11–25
14. Kim ES, Moon SY, Kim SG, et al. Three-dimensional volumetric analysis after sinus grafts. *Implant Dent* 2013;22:170–174
15. Bayraktar M, Gultekin BA, Yalcin S, et al. Effect of crown to implant ratio and implant dimensions on periimplant stress of splinted implant-supported crowns: a finite element analysis. *Implant Dent* 2013;22:406–413
16. Shanbhag S, Shanbhag V, Stavropoulos A. Volume changes of maxillary sinus augmentations over time: a systematic review. *Int J Oral Maxillofac Implants* 2014;29:881–892
17. Kirmeier R, Payer M, Wehrschuetz M, et al. Evaluation of three-dimensional changes after sinus floor augmentation with different grafting materials. *Clin Oral Implants Res* 2008;19:366–372

© 2016 Mutaz B. Habal, MD

Copyright © 2016 Mutaz B. Habal, MD. Unauthorized reproduction of this article is prohibited.

18. Zijderveld SA, Schulten EA, Aartman IH, et al. Long-term changes in graft height after maxillary sinus floor elevation with different grafting materials: radiographic evaluation with a minimum follow-up of 4.5 years. *Clin Oral Implants Res* 2009;20:691–700
19. Jensen T, Schou S, Svendsen PA, et al. Volumetric changes of the graft after maxillary sinus floor augmentation with Bio-Oss and autogenous bone in different ratios: a radiographic study in minipigs. *Clin Oral Implants Res* 2012;23:902–910
20. Mordenfeld A, Hallman M, Johansson CB, et al. Histological and histomorphometrical analyses of biopsies harvested 11 years after maxillary sinus floor augmentation with deproteinized bovine and autogenous bone. *Clin Oral Implants Res* 2010;21:961–970
21. Jensen T, Schou S, Gundersen HJ, et al. Bone-to-implant contact after maxillary sinus floor augmentation with Bio-Oss and autogenous bone in different ratios in mini pigs. *Clin Oral Implants Res* 2013;24:635–644
22. Gapski R, Misch C, Stapleton D, et al. Histological, histomorphometric, and radiographic evaluation of a sinus augmentation with a new bone allograft: a clinical case report. *Implant Dent* 2008;17:430–438
23. Nishibori M, Betts NJ, Salama H, et al. Short-term healing of autogenous and allogeneic bone grafts after sinus augmentation: a report of 2 cases. *J Periodontol* 1994;65:958–966
24. Beretta M, Poli PP, Grossi GB, et al. Long-term survival rate of implants placed in conjunction with 246 sinus floor elevation procedures: results of a 15-year retrospective study. *J Dent* 2015;43:78–86

Schwannoma With Cystic Changes in the Pterygomandibular Space

Dong-Young Chung, DDS, Aditi Sharma, DDS, MSD, So-Young Choi, DDS, PhD, and Jun-Young Paeng, DDS, PhD

Abstract: Schwannomas are tumors that arise from Schwann cells. Although schwannomas can occur almost anywhere in the body where nerve cells are present, they rarely occur in the head and neck region, including the oral and maxillofacial region. Cystic changes in schwannomas are extremely rare. This report is on a case of schwannoma with cystic changes that occurred in the pterygomandibular space.

A 46-year-old woman presented with a complaint of limited mouth opening and pain on the left side of the mandible for 3 months. On panoramic radiography, radiolucency was seen on the left mandibular ramus. On enhanced computed tomography, a 4×3 cm cystic mass was found along the inner side of the left mandibular ramus area. Magnetic resonance imaging showed a multiseptated, well-demarcated cystic lesion on the inner side of the mandibular ramus on the left side. Under general anesthesia, the tumor was excised. The final diagnosis was schwannoma with cystic changes. Lower lip hypoesthesia occurred postoperatively. At the 1-year postoperative follow-up, maximum mouth opening was increased to 44 mm, and lip hypoesthesia was improved.

From the Department of Oral & Maxillofacial Surgery, School of Dentistry, Kyungpook National University, Daegu, South Korea.
Received July 14, 2015.
Accepted for publication November 16, 2015.
Address correspondence and reprint requests to Jun-Young Paeng, DDS, PhD, Kyungpook National University School of Dentistry, Daegu, South Korea; E-mail: jypaeng@gmail.com
The authors report no conflicts of interest.
Copyright © 2016 by Mutaz B. Habal, MD
ISSN: 1049-2275
DOI: 10.1097/SCS.0000000000002394

Key Words: Cystic change, neurilemmoma, pterygomandibular space, S100 protein, schwannoma

Schwannomas are slow growing, benign neoplasms of neural crest Schwann cell origin. They can arise from any peripheral spinal or cranial nerve except the olfactory and optic nerves. The clinical presentation is usually asymptomatic, but focal neurologic signs and symptoms may be associated with nerve compression.[1] Schwannomas are uncommon tumors, with 25% to 48% of all cases occurring in the head and neck region. Of these, 1% occur intraorally, usually in the tongue.[2] Schwannomas in the pterygomandibular space have not been reported so far, based on our search of PubMed—indexed for Medline. These benign tumors occur regardless of age or sex and are painless, insidious, and slow growing.[3] They rarely show an aggressive course. This is a case report of a 49-year-old woman with a schwannoma (neurilemmoma) with cystic changes in the left pterygomandibular space.

CLINICAL REPORT

A 46-year-old woman presented to our department with a complaint of limited mouth opening (25 mm) and pain on left side of the mandible for 3 months. According to the patient, the symptoms had worsened 1 month before her visiting our department. Intraoral examination revealed no notable findings, and mild swelling was observed over the left facial region. Antibiotics and analgesics were prescribed for symptomatic relief. A panoramic radiograph showed well-demarcated radiolucency on the left mandibular ramus (Fig. 1A).

On enhanced computed tomography (CT), a cystic mass measuring 4×3 cm was observed along the medial side of the left mandibular ramus (Fig. 1B). Aspiration was performed, and

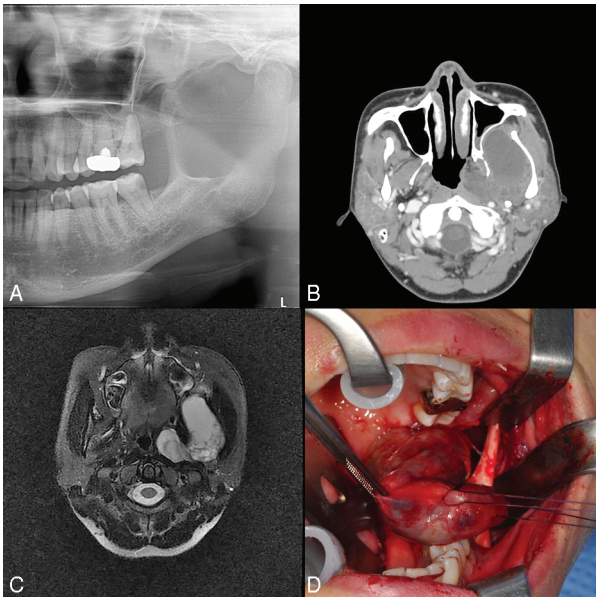

FIGURE 1. A, Panoramic radiograph. Well-demarcated radiolucency is seen in the left mandibular ramus area. B, Enhanced computed tomography scan. A cystic mass measuring 4×3 cm is observed along the medial side of the left mandibular ramus. C, Enhanced magnetic resonance image. A well-demarcated cystic mass and mandibular deformity is seen. D, removal of cystic lesion per oral.

© 2016 Mutaz B. Habal, MD

Copyright © 2016 Mutaz B. Habal, MD. Unauthorized reproduction of this article is prohibited.